



An Observational Study of Pseudodeflect of Tibial Plafond (Incidence, Characteristics and Different Parametric Correlations)

Shayma Zakariya Ahmed  (FKBMS)¹, Sameeah Abdulrahman Rashid  (FKBMS)²

¹Rizgary Teaching Hospital, Erbil , Iraq

²Department of Surgery, College of Medicine, Hawler Medical University, Erbil ,Iraq

Abstract

OPEN ACCESS

Correspondence Address: Shayma Zakariya Ahmed
Rizgary Teaching Hospital, Erbil-Iraq

Email: shayma.zakariya68@gmail.com

Copyright: ©Authors, 2021, College of Medicine, University of Diyala. This is an open access article under the [CC BY 4.0 license](http://creativecommons.org/licenses/by/4.0/)

(<http://creativecommons.org/licenses/by/4.0/>)

Website: <https://djm.uodiyala.edu.iq/index.php/djm>

Received: 9 January 2022

Accepted: 15 February 2022

Published: 23 June 2022

Background: The notch of Harty is a normal variant radiologically and incidentally diagnosed finding but can be mistaken as pathology.
Objective: To identify the incidence and characteristic findings of the notch of Harty.

Patients and Methods: A cross-sectional study was conducted on 121 patients referred to the Radiology department, MRI unit, to undergo ankle MRI through a one-year period (January to December 2020). Cases with significant ankle lesions were excluded. All MRI studies were performed on 1.5 T MR scanners (Aera, Siemens, Arlington).

Results: The notch of Harty was present in 35.5% patients; their age ranged from 5-83 years with a mean age of 38.20 years. The average width of the notch was 5.65mm while the mean depth was 1.04 mm. There was no significant correlation between the presence of the notch of Harty and findings such as rheumatic arthritis, minor trauma, chondral thinning. However, there was significant correlation between the presence of the notch of Harty and subjacent subchondral sclerosis.

Conclusion: The notch of Harty was present among a considerable number of cases with no sex predominance. The notch might be misinterpreted by radiologists as true osteochondral lesions, thus, familiarity with location and appearance of these pseudodeflects will avoid their misinterpretation.

Keywords: The notch of Harty, pseudodeflects, MRI, tibial plafond, osteochondral lesions

Introduction

The notch of Harty is a normal variant radiologically and incidentally diagnosed finding usually located in the anteromedial tibial plafond and is well known among ankle arthroscopy as an anatomical feature that allows for passage of surgical instruments. It is essential not to be mistaken by radiologists

as true osteochondral lesions, to avoid unnecessary intervention by orthopedic surgeons [1].

A number of anatomical variations can be found in the ankle and hind foot. These include accessory ossicles, additional sesamoid bones, variations in the number and

configuration of sesamoid bones, coalitions, bipartitions and variants in the soft tissues, such as accessory muscles. Similar to the pseudodeflect of the anteromedial tibial plafond forementioned, most of them represent developmental abnormalities that constitute incidental radiographic and or MRI findings [2].

Accessory ossicles in most cases are a result of unfused ossification centres. They are seen as subdivisions of existing bones or free elements in the vicinity of normal bone structures. Sesamoid bones have a different anatomical nature. They functionally represent components of a gliding mechanism and are at least partially embedded in tendons, reducing friction and protecting the tendon structure [3].

Osteochondral lesions of the distal tibial plafond must be considered in the differential diagnosis of patients with symptomatic ankles, most commonly occurring at the central-medial tibial plafond [4].

Magnetic resonance imaging (MRI) has opened new horizons in the diagnosis and treatment of many musculoskeletal diseases of the ankle and foot. It demonstrates signal changes in the bones and soft tissues before they become evident at other imaging modalities. Lately we have witnessed an explosion of information regarding the role of MRI in assessing pathologic conditions of the ankle and foot, that is the reason that we used MRI for scanning the patients to evaluate the presence of the pseudodeflect at the anteromedial tibial plafond along with its size, frequency among the general population, its associations with age, minor trauma, marrow edema, and inflammatory disorders [5].

Patients and Methods

This cross-sectional study was carried out on patients referred to the Radiology department MRI unit, to undergo ankle MRI through 1-year period from January to December 2020.

Cases with significant trauma (that cause mal alignment of the ankle joint), with previous operation on ankle joint, history of recent or remote infection of the ankle joint or surrounding bony and soft tissue structures, tumors of the ankle joint or surrounding bones and soft tissues, and cases with improper image quality were excluded.

After the exclusion of patients with the above features, a total of 121 patients were involved in the study. All MRI studies were performed on 1.5 T MR scanners (Aera, Siemens, Arlington).

Study protocol at least included the followings: Sagittal T1 weighted (TR/ TE, 400/11, matrix, 256x256, FOV, 16-18, Slice thickness, 3.5 mm with 0.5mm inter slice gap, echo-train length {ETL}, Sagittal T2 weighted (TR/ TE, 3450/31, matrix, 256x256, FOV, 16-18, Slice thickness, 3.5 mm with 0.5mm inter slice gap, echo-train length {ETL}, 8, Sagittal T2 weighted with fat suppression (TR/ TE, 2550/86, matrix , 256x256, FOV, 16-18, Slice thickness, 3.5 mm with 0.5mm inter slice gap, echo-train length {ETL}, 8, Axial PD (TR/TE, 4500/38, matrix, 480x320, FOV , 14, Slice thickness, 3 mm with 1 mm inter slice gap, echo-train length {ETL}, 10, coronal PD (TR/ TE, 3900/27, matrix, 480x384, FOV 13, Slice thickness, 3.5 mm with 0.5mm inter slice gap, echo-train length {ETL}, 9, Coronal T1 weighted (TR/ TE, 2200/ 47, matrix , 256x256, FOV, 14, Slice thickness, 3.5 mm

with 0.5mm inter slice gap, echo-train length {ETL}, Coronal T2 weighted with fat suppression TR/ TE, 400/11, matrix, 256x256, FOV, 16-18, Slice thickness, 3.5 mm with 0.5mm inter slice gap, echo-train length {ETL}, 8.

Image analysis was performed on a special workstation (EIZO - SIEMENS) and cases were reviewed for presence of notch, its depth and width, presence of joint effusion, presence of subchondral edema, presence of subchondral sclerosis, presence of chondral thinning and presence of osteochondral lesions.

Statistical Analysis

Data were entered; double-checked and analyzed using Statistical Package for Social

Science (SPSS), version 26. Descriptive analysis included calculation of frequencies, percentages of variables, paired t- test, Chi Square and p-value level of 0.05 was regarded as a biostatistical significant level.

Results

Out of 121 studied cases, the percentage of cases that had a notch of Harty was 35.5%. Among those cases, 51.2% of them were female and 48.8% were male. The age of the participants ranged from 5-83 years with a mean age \pm SD of 38.20 ± 17.16 years. The average width of the notch was 5.65mm while the mean depth was 1.04 mm as a result the mean size was 5.93 mm^2 Table (1).

Table (1): Description of study characteristics: gender, age and size of notch of Harty

Notch of Harty	Male No (%)	Female No (%)	Age (year) Mean \pm SD	Width (mm) Mean \pm SD	Depth (mm) Mean \pm SD	Size (mm^2) Mean \pm SD
Yes n=43	21 (48.8)	22 (51.2)	38.02 ± 16.49	5.65 ± 0.68	1.04 ± 0.17	5.93 ± 0.23
No. n=78	33 (42.3)	45 (57.7)	38.29 ± 16.62	0	0	0
Total n=121	54 (44.6)	67 (55.4)	38.20 ± 16.17	5.65 ± 0.68	1.04 ± 0.17	5.93 ± 0.23

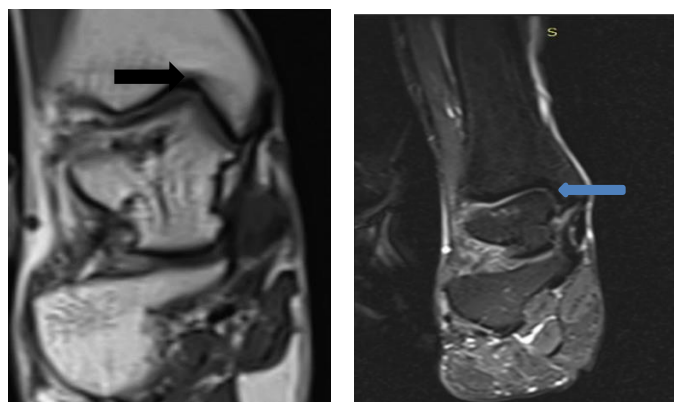


Figure (1) A: Coronal T1 weighted MRI
(B): Coronal T2 weighted with fat sat MRI of a 48 years old man with ankle pain but no history of trauma or inflammatory joint disease, showing a small defect (Notch of Harty)

Among the subjects with notch of Harty, subjacent subchondral sclerosis was the most frequent finding and found in 83.7% of them, then followed by chondral thinning in 65.1% of the cases, while the notch was seen in only 2 cases with known Rheumatoid arthritis.

The results of Table (2) show that there was a significant statistical association between the presence of Harty notch and subjacent subchondral sclerosis. Majority of patients (83.7%) who had the notch had subjacent subchondral sclerosis too, while only (56.4%)

of the patients without Harty notch also had subjacent subchondral sclerosis. Pearson Chi square test was done and the p – value was 0.002.

In contrast, there was non-significant statistical association between the presence of the notch of Harty and the other variables like rheumatic arthritis, chondral thinning and osteochondral lesion as is seen in Table (2) Pearson Chi square tests were done and p – values were more than 0.05.

Table (2): Association between notch of Harty and rheumatic arthritis, subjacent subchondral sclerosis, chondral thinning and osteochondral lesion

Notch of Harty	Rheumatic arthritis	SS Sclerosis*	Chondral thinning	Osteochondral lesion
Yes	2 (4.7%)	36 (83.7%)	28 (65.1%)	8 (18.6%)
No	5 (6.4%)	44 (56.4%)	51 (65.4%)	14 (17.9%)
Total	7 (5.8%)	80 (66.1%)	79 (65.3%)	22 (18.2%)
p-value	0.157	0.002	0.451	0.921

*Subjacent subchondral sclerosis

The findings of Table (3) reveal that there was a non-significant statistical relationship between Notch of Harty and minor trauma,

ankle joint effusion, and subchondral edema. Chi square test was done and p–values were more than 0.05.

Table (3): Association between notch of Harty and minor trauma, ankle joint effusion and subchondral edema

Notch of Harty	Minor Trauma	AJ Effusion*	SC Oedema**
Yes	6 (14%)	7 (16.3%)	6 (14%)
No	8 (10.3%)	7 (9%)	8 (10.3%)
Total	14 (11.6%)	14 (11.6%)	14 (11.5%)
p-value	0.563	0.247	0.563

*Ankle joint effusion

**Subchondral edema like signal

Discussion

The current study reported the incidence of notch of Harty and describing its characteristics. Among the study participants, a notch of Harty was present in almost 36% of the cases. However, other previous studies reported higher incidence of the notch of Harty. For instance, Boutin *et al* [7] found this anatomic feature among 45% on routinely performed MRI investigations. Ray

et al [8] also reported higher percentage of the presence of notch of Harty that found by direct anatomical inspection. This might suggest that the percentages of MRI findings of the notch is less than to what is found by direct inspection [7].

Our findings indicate that the notch of Harty is present approximately equally in both genders (male and female). This is in accordance with what has been documented by Boutin *et al* [7]. The authors found no sex

predominance of the notch of Harty as the notch was identified among equal proportion of both sexes.

The characteristics finding of the notch in our study is comparable to the previous study [7] identifying similar measures of the notch such as its width and depth. Boutin *et al* [7] reported that the mean width of the notch was 6.2mm, which is slightly higher compared to our finding (mean width: 5.65mm). In addition, they also identified that the mean depth of the notch was 1.2mm, which is again comparable to our finding (i.e., 1.04mm depth).

In the current study, the mean age (\pm SD) of our participants with the notch was 38.2 (16.49), This might suggest that the notch might be detectable with advancing age. Although Boutin *et al* [7] found the notch among the participants with a mean age of 43.1; this was not statistically significant compared to those without the notch of Harty. Boutin *et al* [7] concluded that the notch of Harty could be regarded as a developmental finding. Additionally, Ray [8] concluded that the notch could be considered as a normal anatomic variant.

Our analysis showed that among the participants with the notch of Harty, the most frequent finding was SS sclerosis (83.7%) and chondral thinning (65.1%). However, we found no statistically significant relationship between the notch of Harty and other variables of the notch except for the SS sclerosis (P value = 0.002). Similarly, comparing the patients with notch of Harty with those without the notch, Boutin *et al* [7] also found no statistically significant association between the notch of Harty and incidence of subcortical osteosclerosis

subjacent, ankle joint effusion, osteochondral lesions or subchondral bone marrow edema.

The notch of Harty is described as anatomical feature [8, 9], radiologists may misinterpret this normal anatomic notch as true osteochondral lesions [1, 7]. This is true for other pseudodefects in the body, such as that of the distal humerus at the junction of the lateral epicondyle and capitellum, as it might be misinterpreted as osteochondral fracture of the distal humerus. In addition, normal anatomic variants at hip MRI may mistakenly be considered as abnormalities. Therefore, familiarity with the location and appearance of these pseudodefects will avoid their misinterpretation [10, 11].

Areas for future research include the following: the effect of patient factors like body mass index, ethnicity, heredity and their correlation with the notch of Harty. [6].

Conclusions

The incidence of notch of Harty was present among a considerable number of cases and there was no sex predominance of notch of Harty. There was a significant correlation between the presence of the notch of Harty and subjacent subchondral sclerosis. This normal anatomic notch might be misinterpreted by radiologists as true osteochondral lesions, thus, familiarity with the location and appearance of these pseudodefects will avoid their misinterpretation.

Recommendations

Furthermore study is recommended to be carried out by other researcher to determine other aspects of this subject.

Source of funding: The current study was funded by our charges with no any other funding sources elsewhere.

Ethical clearance: The study was carried out and ethical clearance was obtained by the medical care committee of the Kurdistan higher council of medical specialites .

Conflict of interest: Nil

References

[1] Practical Reviews. Anatomic Feature That Ankle Arthroscopists Know That You Should Know Too. [Internet]. 2021; [cited 2021 Nov 20]. Available from: https://practicalreviews.com/PracticalReview/sinRadiology/Articles/The_Notch_of_Harty_Pseudodeflect_of_the_Tibial_Plaf_159550.aspx

[2] Kelikian AS and Sarrafian SK, Sarrafian's anatomy of the foot and ankle: descriptive, topographic, functional. 2011: Lippincott Williams & Wilkins. ISBN-13: 978-0781797504

[3] Elias I, Raikin SM, Schweitzer ME, Besser MP, Morrison WB, and Zoga AC. Osteochondral lesions of the distal tibial plafond: localization and morphologic characteristics with an anatomical grid. 2009. [PMID: 19486630] [[CrossRef](#)]

[4] Mellado JM, Ramos A, Salvadó E, Camins A, Danús M, Saurí A. Accessory ossicles and sesamoid bones of the ankle and foot: imaging findings, clinical significance and differential diagnosis. Eur Radiol. 2003;13 Suppl 4:L164-177.[PMID]: 16440220[[CrossRef](#)]

[5] Rosenberg ZS, Beltran J, Bencardino JT. From the RSNA Refresher Courses. Radiological Society of North America. MR imaging of the ankle and foot. Radiographics. 2000;20 Spec No:S153-179. [PMID: 11046169] [[CrossRef](#)]

[6] Allahabadi S, Allahabadi S, Allala R, Garg K, Pandya NK, Lau BC. Osteochondral Lesions of the Distal Tibial Plafond: A Systematic Review of Lesion Locations and Treatment Outcomes. Orthop J Sports Med. 2021;9(4):2325967121997120. [PMID: 33948443] [[CrossRef](#)]

[7] Boutin RD, Chang J, Bateni C, Giza E, Wisner ER, Yao L. The notch of Harty (pseudodeflect of the tibial plafond): Frequency and characteristic findings at MRI of the ankle. AJR Am J Roentgenol. 2015;205(2):358-363. [PMID: 26204288][[CrossRef](#)].

[8] Ray RG. Anatomical variation of the tibial plafond: the anteromedial tibial notch. J Foot Ankle Surg. 1995 ;34(6):597. [PMID: 8646214] [[CrossRef](#)].

[9] Dijk CNv. Arthroscopic Anatomy. [Internet]. Musculoskeletal Key. 2017; [cited 2021 Nov 25]. Available from: <https://musculoskeletalkey.com/arthroscopic-anatomy/>

[10] Rosenberg ZS, Beltran J, Cheung YY. Pseudodeflect of the capitellum: potential MR imaging pitfall. Radiology. 1994;191(3):821-823. [PMID: 8184072] [[CrossRef](#)]

[11] Nguyen MS, Kheyfits V, Giordano BD, Dieudonne G, Monu JU. Hip anatomic variants that may mimic abnormalities at MRI: labral variants. AJR Am J Roentgenol. 2013;201(3):W394-400. [PMID: 23971471] [[CrossRef](#)]

دراسة مبنية على مشاهدة عيب كاذب في عظم القصب من مفصل الكاحل الوقوع، (صفة مميزة وارتباطات البارامترية المختلفة)

د. شيماء زكريا أحمد^١، د. سميرة عبد الرحمن رشيد^٢

المخلص

خلفية الدراسة: شق هارتي هو ظاهرة طبيعية، يشخص بالصدفة أثناء الفحص الاشعاعي و قد يخطأ على انه مرض. **اهداف الدراسة:** لتعرف على نسبة شيوع هذه الظاهرة و خصائص شق هارتي. **المرضى والطرائق:** الاشعة المقطعية اجريت على ١٢١ حالة التي تم تحويلها الى قسم الاشعة شعبة الرنين المغناطيسي لتصوير مفصل الكاحل لفترة ما بين كانون الثاني الى كانون الاول ٢٠٢٠ ، الحالات التي لها الصدمات الشديدة (حوادث كبيرة أدت الى انحياز في هيئة المفصل) أو كسور في العظام المتجاورة ، تشوهات خلقية في المفصل، كتل أورامية حول المفصل، العمليات الي اجريت لمفصل الكاحل او العظام المتجاورة او العضلات المتجاورة تم استبعادها من حالات البحث . كل الحالات تم اجرائها على جهاز الرنين المغناطيسي قياس ١,٥ تسلا من انواع شركات (سيمنس ، ايرا ، نارلينكتون). **النتائج:** شق هارتي كان موجودا في ٤٣ مريضا (٣٥%) ، ٢٢ (٥١%) منهم كانوا اناثا ، و ٢١ (٤٨,٨%) منهم كانوا ذكورا. عمر المشاركين تراوحت من (٥ الى ٨٣) سنة مع متوسط (٣٨,٢ +/- ١٧,١٦) سنوات. متوسط عرض الشق تراوحت بين ٥,٦٥ مم في حين متوسط العمق كان ١,٠٤ مم . لم يوجد علاقة مترابطة مهمة بين تواجد شق هارتي و الموجودات مثل (التهاب المفصل الروماتويدي، حوادث بسيطة، ترقق الغضروف، انصباب مفصل الكاحل، اي اشارة منها وذمة تحت الغضروف، تواجد الافات العظمية الغضروفية)، و مع ذلك كان هناك ارتباطا كبيرا بين تواجد الشق هارتي و تصلب الغضروفي السفلي . **الاستنتاجات:** الشق هارتي كان موجودا في عدد كبير من الحالات ولم يكن للجنس دورا في نسبة الوقوع . هذا الشق التشريحي الطبيعي العادي قد يخطأ عند أطباء الأشعة على أنها افة عظمية غضروفية و هكذا معرفة المنطقة و مظاهر هؤلاء العيوب الكاذبة يمنع حدوث تفسيرات خاطئة. **الكلمات المفتاحية:** شق هارتي، جهاز الرنين المغناطيسي، افة عظمية غضروفية، عيب كاذب، الجهة الامامية الوسطى التحتية من عظم القصب.

البريد الإلكتروني: shayma.zakariya68@gmail.com

تاريخ استلام البحث: ٩ كانون الثاني ٢٠٢٢

تاريخ قبول البحث: ١٥ شباط ٢٠٢٢

^١مستشفى زكريا التعليمي - اربيل - العراق

^٢كلية الطب - جامعة هولير الطبية - اربيل - العراق