

## Cherubism: Case Report and Review of Literature

Sabah Nuri Mizel (PhD,FKBMS)<sup>1</sup> and Ali F Al-Zubaidee (BDS,  
FFDRCS(Irel),FDSRCS(Eng), FDSRCPS(Glasg)<sup>2</sup>

<sup>1</sup>College of Dentistry, AL- Kitab University, Erbil, Iraq

<sup>2</sup>Professor and Consultant of at Kurdistan Board of Medical Specialties-Head of Council of Dental Specialties-Erbil- Iraq

Correspondence Address:

Sabah Nuri Mizel

College of Dentistry, AL- Kitab University, Erbil, Iraq

email: [sabah.dubaisy@gmail.com](mailto:sabah.dubaisy@gmail.com)

Received: 8 March 2021

Revised: 4 April 2021

Accepted: 13 June 2021

Published: 25 October 2021

Diyala Medical Journal 2021;21(1): 44-54

### Abstract

Cherubism is an autosomal dominant, very rare benign fibro-osseous lesion, with an estimation of only 300 cases have been reported worldwide. Cherubism is characterized clinically by bilateral symmetrical self-limiting jaw enlargement starts in the childhood or early teens. Mandible is mostly affected although maxilla and zygomatic bones may be involved but to a lower extent), and is associated with tooth displacement and severe malocclusion. Histopathologically, it is indistinguishable from giant cell lesions therefore the clinical manifestations of the disease remain the Gold Stone.

**Keywords:** Cherubism, mandible, maxilla, bilateral palatal swelling

### Introduction

Cherubism is a rare, non –neoplastic, self-limiting, hereditary fibro-osseous disorder of the jaws [1]. It had been defined as a different kind of the other multilocular cystic diseases of the jaws by William A. Jones in 1933, who had discovered multiple siblings affected with Cherubism in the same family, hence, got the precedence in naming the disease "Cherubism" a name that describes extra -oral manifestations of a cherubic child face with upward casting eyes and full round

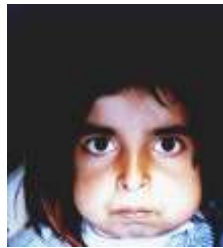cheeks resembling the upward gaze and chubby face of angles [2]. Due to the disease rarity, only 300 cases of Cherubism had been described to date [3]. The disease is inherited and the type of inheritance is autosomal dominant through mutation of SH3-binding protien2(SH3bp2) gene, leading to the formation of bilateral multilocular radiolucent cystic lesions containing fibrous tissue leading to bilateral enlargement of the affected jaw, which is in the most cases the

mandible, sometimes both the mandible and the maxillae are both affected [3].

### Case Report

A 4 years old boy attended the oral and maxillofacial surgical dental clinic, accompanied by his parents, who complained of painless symmetrical bilateral swelling in their son's face, involving mainly the upper and lower jaws.

The Extra-oral clinical examination revealed bilateral hard, non-tender swelling affecting the maxillae and the mandible jaw bilaterally (chubby face). Both eyes were exophthalmos and upward looking (upward gaze), normal nasal breathing and swallowing.

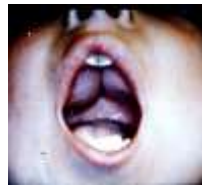

**Figure(1):** Chubby face, with upward gaze

### Intra-oral examination

Bilateral hard mandibular bucco-lingual expansion with bilateral maxillae swelling

bucco-palataly and striking intra-oral bilateral palatal bony swelling and downward bulging.

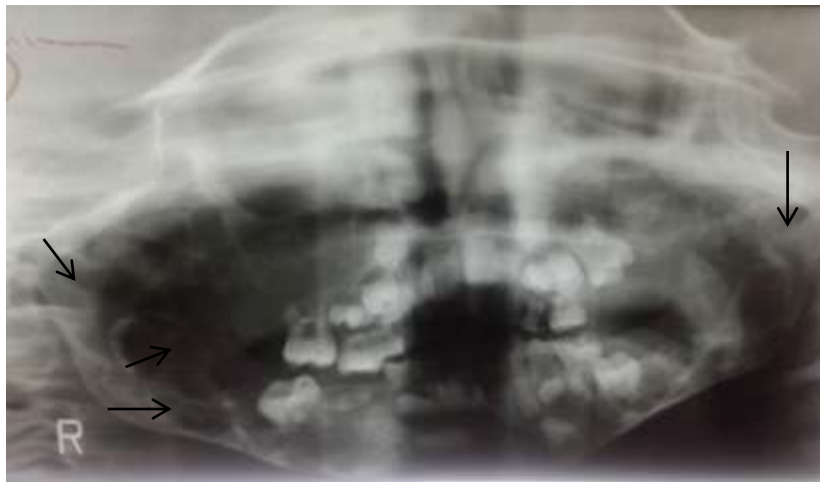

**Figure (2):** Bilateral intra-oral palatal bony swelling and downward bulging

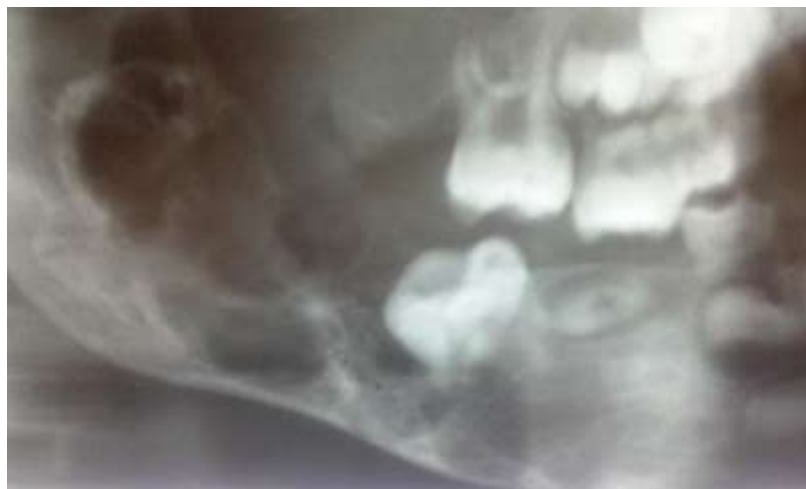### Radiograph Findings

The panoramic view showed bilateral multi-ocular cystic lesions involving the mandible and maxillae, sparing the coronoid processes, but involving the right condyle. The left condyle is intact. Deciduous teeth were malaligned and shedding of the upper a

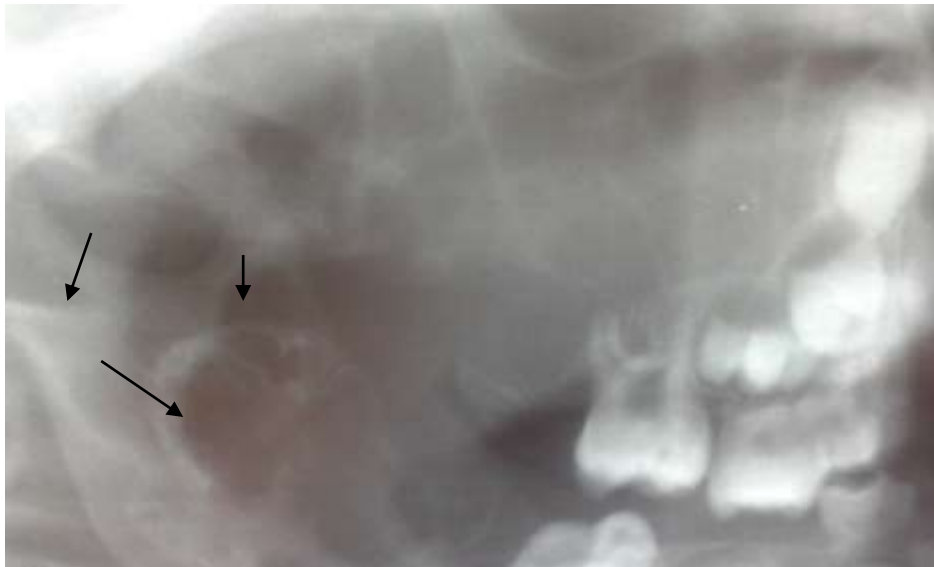nterior deciduous teeth and most of the lower deciduous teeth with only lower right C, and lower left C, D, and E are remaining. There were only five maxillary deciduous teeth remaining which are upper right C, D, and E, and upper left D, and E.



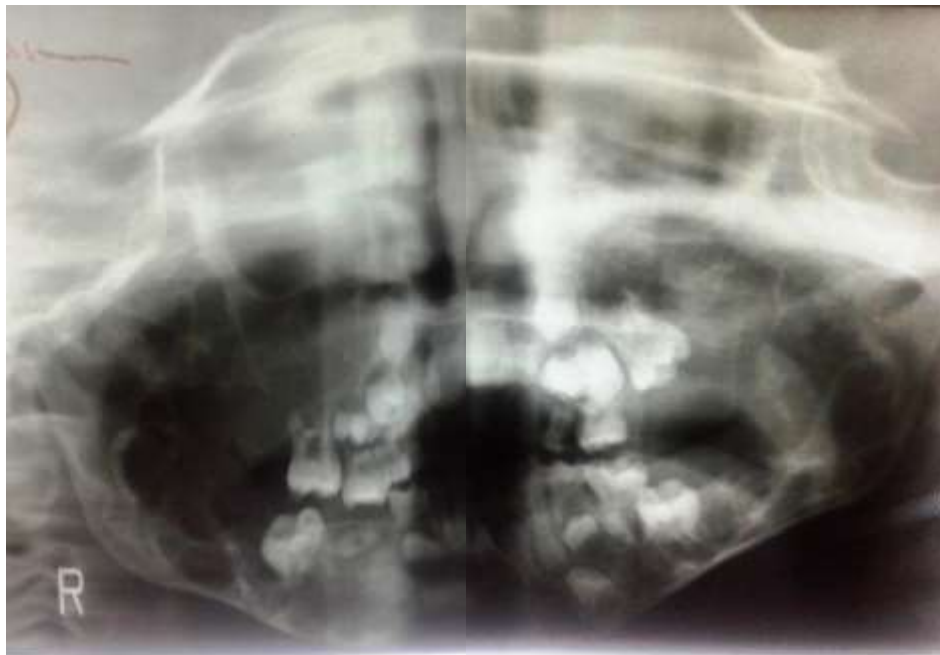**Figure (3):** A panoramic view showing multi-locular cystic lesions involving the maxillae and the mandible ( arrowed ), the right condyle is affected , however , the left one is intact (arrowed) , with maxillary and mandibular deciduous teeth mal-alignment and anterior teeth shedding off



**Figure (4):** Multi-locular cystic lesions of the mandibular right side ranging from the condyle down to the ramus below the coronoid process downward to the angle of the mandible, then to the body



**Figure (5):** Showing the multilocular cystic lesions starting in the ramus of the right mandible at the level of the sigmoidal notch, sparing the coronoid, however, the right condyle is also involved (arrowed) .The right maxilla shows multi-locular cystic radiolucency



**Figure (6):** Comparison between right and Left maxilla and mandible sections of the panoramic view showing

The multi-locular cystic lesions at the left side at the angle and body of the mandible, with the left side less severity than the right side which shows more destructive multilocular lesions at the right maxillary

molar and tuberosity regions and right mandibular condyle , ramus , angle , and body.

Right side bony expansion bucco-lingual at the mandible, and bucco –palatal of the

maxilla is much more than that at the left side.

## Discussion

Cherubism is defined by the presence of bilateral multi-ocular expanding cystic like lesions that appear lucent in the x-ray affecting either only the mandible or sometimes may affect both mandible and maxillae with affecting age ranging from two to seven years. Hence, the resulting fullness of the face (chubby face) may lead to the swelling of the submandibular lymph nodes, and the expanded masses of the dysplastic fibrous soft tissue can infiltrate the floor of the orbit, leading to the upward movement of the eyeball showing up the sclera under the iris giving the feature of upward gaze[2]. It's a self-limiting disease and regresses after puberty.

Previously, it had been mentioned that this disease is only affecting bones of the face. however, articles have been published about Cherubism involving temporal bone, ribs and humerus [3].

## Epidemiology

Cherubism is a rare disease that just 300 cases are reported worldwide and in all ethnic groups[2,3] with 70% occurrence in females and 90% in males[1], with more predominance to male, and mostly affecting the lower jaw[4].

## Causes

### 1-Genetic

#### A-Familial type Cherubism

Cherubism is mostly caused by chromosome 4p16 having gene SH3BP2 on it, this gene will be affected by the mutation. This mutation is inherited as an autosomal dominant, and the disease phenotype shall

appear in all future generations with different severity levels [4].

#### B-Sporadic non Familial type Cherubism

Here in this type, the mutation randomly occurs in the child with no previously affected siblings, named (Sporadic non-familial Cherubism) [4].

Other genetic diseases may present in combination with Cherubism like Noonan Syndrome, Ramon Syndrome, and Fragile X Syndrome [4].

#### 2-Other Causes

Like mesenchymal alterations during jaw development, an odontogenic origin, hormonal, and traumatic factors [1].

#### Pathophysiology

The effects of mutation of the gene SH3BP2 is controversial[4], however, there are some researchers who believe that the mutation in SH3BP2 will affect a six amino acid sequence of proteins which are important in affecting cell regulatory proteins attachment which necessary in signaling cells degradation, altering their location, affecting cells activity, and promoting or preventing proteins interactions. The end result newly formed protein due to this mutation shall disable critical signaling pathways in cells responsible for the maintenance of bone tissue and in some immune system cells [5]. Hence, the highly active/elevated amino acid protein levels in macrophage/osteoclast cell precursors will cause an increase in the amount of osteoclast genesis, which in turn, lead to more bone destruction, together with signaling inflammatory mediators like TNF- $\alpha$ [5]. The excessive bone loss and inflammatory reaction will lead to more bone destruction with fibrous tissue formation and

cystic growth in the jaws and/or facial bones which are characteristics of Cherubism[4].

### **Clinical Manifestations**

Cherubism is a disease that had been thought to affect mainly the mandible jaw bones ( many of the cases are limited to the mandibles), and the condyles are almost always intact [1]. However, in the current case, both mandibles and the maxillae were involved together with the involvement of the right mandibular condyle, a rarity let to the reporting of this case. The affected child appears normal at the time of birth; however, the swelling starts at the age of one year to seven years of age with the usual first presentation as a bilateral asymptomatic expansion of mandibular bone at the angle area, followed by progressive swelling of the cheeks. On palpation, the swelling was firm to hard and sometimes associated with regional lymphadenopathy [1].

Cherubism, as the specific characteristic feature of the given name; there is a disproportionate enlargement of the patient's face because of deposition of atypical cystic bone lesions and fibrous tissue formation. Other functions can also be impaired like speech, respiratory, masticatory, and swallowing. In our presented case the affected child started the bilateral swelling at the age of four years with no respiratory, masticatory, or speech impairment.

### **Extra cranial involvement**

Cherubism is mainly affecting the mandible bones. But cases have been reported about the involvement of other bones like the Zygoma and the ribs.

The first case was for a girl aging 17-year old as a member of a family having other three affected siblings with Cherubism, showed

painless lesions at the anterior ends of her ribs without any expansion [2].

The second case was for a boy aging eight years old complaining from facial swelling bilaterally, associated with radiographic features of Cherubism that had been found invading both the zygomatic bones and the anterior end of the ribs bilaterally [2].

The third case was for a child aging 6-years-old with Cherubism showed asymptomatic multilocular lesions in the ribs [2].

Cherubism is associated with fingers clubbing and craniosynostosis and have been described in a single family [2]. Our Cherubism presented case was confined to the mandible and maxillae bones with no extracranial involvement.

### **Ophthalmic Manifestations**

In the severe cases of Cherubism involving the maxillae, there is the upward displacement of the eyeball together with retraction of the eyelids occur as a result of the invasion of the fibro-osseous tissue lesions which in these severe cases extending to reach the orbital walls laterally and inferiorly leading to the end result of upward gaze, that may lead to diplopia and sometimes, loss of vision[2,4]. In our presented case the Cherubic child showed upward gaze, however, with no diplopia or vision loss.

### **Dental Impact**

The development of fibro-osseous lesions leads to early deciduous tooth loss starts at the age of 3-years of age. Also, hypodontia, displacement, and impaction may affect the permanent teeth. However, the oral mucosa remains intact with no manifestations systemically. When the maxilla is involved, in most cases, it may be more severely

affected than the mandible [4]. In our presented case there is the involvement of both mandible and maxillae, with deciduous teeth mal-alignment and anterior teeth shedding off.

### Grading System

The different clinical pictures of Cherubism are related to the magnitude of changes secondary to mutations or incomplete penetrance. We have mainly two grading system for Cherubism:

A-The grading system for Cherubism proposed by Ramon and Engel berg:

Grade 1-Involvement of both mandibular bones bilaterally with the ascending ramus bilaterally (as seen in our patient).

Grade 2-Involvement of both maxillary tuberosities, and both mandibles with their ascending ramus.

Grade 3-Severe involvement of all the maxillae and mandibles bilaterally, sparing the condylar head.

Grade 4- Involvement of the floor of the orbits causing orbital.

Compression with Severe involvement of all the maxillae and mandibles bilaterally, sparing the condylar head [6].

B-Another grading system for Cherubism is by Motamedi and Raposo-Amaral [2].

**Table(1):Grading System for Cherubism [2]**

| <b>Table 1 Cherubism grading system according to Motamedi (1998) and Raposo-Amaral (2007)</b>  |  |
|--|--|
| Grade I<br>Lesions of the mandible without signs of root resorption  | Class 1 solitary lesion of the mandibular body<br>Class 2 multiple lesions of the mandibular body<br>Class 3 solitary lesion of the ramus<br>Class 4 multiple lesions of the rami<br>Class 5 lesions involving the mandibular body and rami            |
| Grade II<br>Lesions involving the mandible and maxilla without signs of root resorption  | Class 1 lesions involving the mandible and maxillary tuberosities<br>Class 2 lesions involving the mandible and anterior maxilla<br>Class 3 lesions involving the mandible and entire maxilla  |
| Grade III<br>Aggressive lesions of the mandible with signs of root resorption  | Class 1 solitary lesion of the mandibular body<br>Class 2 multiple lesions of the mandibular body<br>Class 3 solitary lesion of the ramus<br>Class 4 multiple lesions of the mandibular rami<br>Class 5 lesions involving the mandibular body and rami |
| Grade IV<br>Lesions involving the mandible and maxilla and showing signs of root resorption  | Class 1 lesions involving the mandible and maxillary tuberosity<br>Class 2 Lesions involving the mandible and anterior maxilla<br>Class 3 lesions involving the mandible and entire maxilla  |
| Grade V<br>The rare, massively growing, aggressive, and extensively deforming juvenile cases involving the maxilla and mandible, and may include the coronoid and condyles |  |
| Grade VI<br>The rare, massively growing, aggressive, and extensively deforming juvenile lesions involving the maxilla, mandible and orbits                                 |  |

Here we report a case of Cherubism with Grade 4 according to Ramon and Engel berg's grading system; the patient has exophthalmia, but after consultation with the ophthalmologist showed that he has normal vision.

### Diagnostic Imaging

The routine OPG radiographic examination is the most feasible easily performed imaging technique for a child with Cherubism. The radiograph findings of Cherubism are bilateral expansive soap bubble-like

multilocular radiolucent lesions at the affected bones affecting the mandible mainly at the angle and the ascending ramus may extend to involve the mandibular body. Maxillary and orbital involvements are less frequent. Different types of dental abnormalities may be seen like floating teeth, along with multiple retained deciduous teeth, root resorption, delayed eruption, and displaced teeth [7].

Computed tomography is considered superior to Orthopantomogram in the diagnosis of bone lesions because it can provide better observation of lesions and their surrounding structures which can be analyzed by multiplanar reformation and three-dimensional reconstructed images [1].

Magnetic resonance imaging has higher soft tissue resolution, hence, it's widely used to evaluate musculoskeletal lesions and it is often superior to CT in histological diagnosis and provides more information about the lesions and the surrounding

Soft tissues [1].

### **Histopathological Examination**

The histopathological picture of Cherubism shows many giant-cells and mononuclear or stromal cells, with non-neoplastic fibrotic lesions, which is a histopathological picture showing similarity to many other giant cell lesions affecting the jaws, therefore it's improbable to diagnose Cherubism depending only on the histopathological picture [2].

### **Differential Diagnosis**

The differential diagnosis of Cherubism is:

- 1-Central giant cell granuloma (CGCG)
- 2- Multiple giant-cell lesion syndromes
- 3- Fibrous dysplasia
- 4-Hyper-parathyroidism (brown tumors)

5-Clinically similar to Ramon syndrome [7].

It is easy to differentiate CGCG from Cherubism through both histological pictures and radiological pictures since CGCG is always unilocular, whereas the lesions of Cherubism are usually multilocular [8]. Low radiation doses of Cone-beam computed tomography (CBCT) can be used to detect small lesions without any obvious enlargement of the face. Two cases had been reported diagnosed as central giant cell lesions and Cherubism with the use of CBCT [8].

It is easy to differentiate multiple giant-cell lesion syndromes from Cherubism according to their rarity and their association with other clinical systemic features like developmental delay, short stature, pulmonary stenosis with similar clinical manifestations of fibrous lesions affecting the jaws like the condition found in Cherubism [8].

The differentiation of Fibrous dysplasia of the jaw from Cherubism is easily made since. A-The fibrous dysplasia occurs always unilaterally and tends to affect only the maxilla rather than the mandible, while Cherubism has a tendency to affect the mandible, bilaterally.

B- The radiographical picture of Cherubism is bilateral multilocular soap-bubble multilocular lesions while the radiographical picture of fibrous dysplasia is characterized by fingerprint or orange peel appearance that merges with the adjacent normal unaffected bone [8].

The age of onset of Brown tumors is usually in adulthood, arise as a result of parathyroid hormone effects on bone tissue in persons with hyperparathyroidism while Cherubism



starts at childhood and regress after puberty. So by investigating serum concentrations of calcium, parathyroid hormone, and alkaline phosphates which are elevated, in this case we can easily differentiate it from Cherubism in which there are no biochemical changes[8].

A coincidental association of only one case of coronal and sagittal craniosynostosis had been reported in association with Cherubism. A case of combination between Cherubism with Ramon syndrome, neurofibromatosis, fragile X syndrome had been reported [8].

#### **Mutation Confirmation Test**

The diagnosis of any possibility of the upcoming generations of the same family to inherit the disease is made by gene testing[8], however, if there is a negative family history, this will not exclude the likely hood of Cherubism, since there is a sporadic non-familial type of Cherubism in addition to the inherited type[2].

#### **Management and Treatment Modalities**

Since till now no treatment had been established for Cherubism, so the doctors can only offer the precise diagnosis for their patients, nothing else can be given other than that since the disease is self-limiting and can spontaneously regress in growth after puberty[9].

In case of mild levels of Cherubism, where no maxillofacial complications nor facial disharmony can be noticed, in this condition, no ant treatment intervention is indicated, since the disease process is self-limited after puberty. However, follow up is indicated annually, through both clinical and radiological evaluations till regression of the disease condition [2].

On the other hand, surgical option is only allowed if there is a functional or esthetic problem during the disease process like vision problem, proptosis, facial disharmony, and nasal obstruction. The surgical operations should be done only after maturation and ceasing of the disease progression include surgical contouring/ curettage and partial resection.

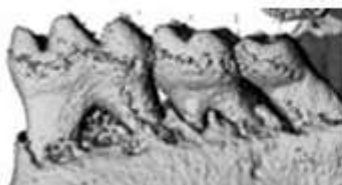
However, only the degree of the severity of the disease condition can give the decision of having early surgical intervention. Severe aesthetic or functional problems may justify intervention prior to puberty. Orbital surgery may be required in rare cases when tumor tissue invades the floor of the orbits to a degree where it leads to the displacement of globes or loss of vision is suspected due to optic atrophy [2].

Yasuyoshi Ueki, in association with his research team at School of Dentistry University of Missouri Kansas City, and depending on the fact that inflammatory conditions in Cherubism related to an increase in tumor necrosis factor-alpha (TNF-alpha) level in tissues, and by using lab mice, Ueki treated the mutated cherubism mice having the SH3BP2 mutations with a blocking drug of the TNF-alpha function . However, Ueki's research team found that regarding the use of this drug, timing is everything, the earliest given, the best results. The drug (TNF-alpha blocker like Etanercept) did not reduce inflammation in two and a half month -old genetically modified mice that already had signs of active inflammation, which means [9].

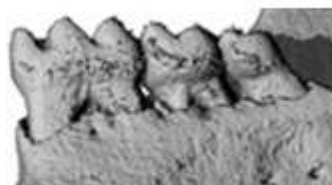
Ueki's research studies showed that Etanercept (The TNF-blocking drug) can help to prevent facial enlargements and

jawbone fibrousseous destructing lesions in early mutated young mice and should be given continuously to avoid the appearance of facial swelling and jawbone destruction and it will do not help mice that already have the cherubism clinical features.

Another newly emerged treatment approach and due to the inactivity of the Etanercept



drug in treating the mutated laboratory mice with the clinical picture of Cherubism, Ueki's research team in the February 2015 issue of *Bone* reported bone marrow transplantation for those laboratory mice with clinical signs of Cherubism, from a healthy donor mouse, in this way they noticed a reduction of the inflammatory bone loss process[9].



**Figure(7):** The micro-CT scans show

The left scan: Without treatment, the mutated mice with Cherubism had inflammatory bone loss appears as shadowy pits along the jawbone.

The right scan: After bone marrow transplantation the mutated mice with Cherubism had reduction in the inflammatory bone loss process appears as disappearance of the pits.

### Recommendations

Cherubism, in spite of the disease rarity, should be put in mind, especially in early childhood, for the differential diagnosis of any bilateral asymptomatic expansion of the mandibular bone, followed by bilateral progressive enlargement of the cheeks. There is an ultimate need for multi disciplinary team approach (oral maxillofacial medicine specialist, Ear-Nose-Throat specialist and an ophthalmologist specialist) for the regular clinical follow-up of the patient, including Orthopantogram radiological examination which is more feasible by the patient, followed Computed Tomography and Magnetic Resonance Imaging to evaluate the

extent and prognosis of the musculoskeletal fibrousseous lesions and their surrounding structures.

**Source of funding:** Nill.

**Ethical clearance:** The study was approved by the academic ethical Committee of the Kurdistan Board for medical specialties in 2020. Consent to write and publish this case report was given by signing an informed consent approved by the Committee for Medical Research Ethics at the Kurdistan Board for Medical Specialties.

**Conflict of interest:** Nill

### References

- [1]Zhaoyang Yu, MD, Miao Zhai, MD, Wei Gan, MD, Hong Zhang, MD, Yuxia Zhou, MD, PhD, and Haixia Wen, MD Cherubism With Bilateral Mandible and Maxilla Involvement A Case Report.
- [2]Maria E Papadaki1, Steven A Lietman, Michael A Levine, Bjorn R Olsen, Leonard B Kaban, Ernst J Reichenberger: Cherubism: best clinical practice.Papadaki *et al*. Orphanet

Journal of Rare Diseases 2012, 7(Suppl 1):S6  
[.http://www.ojrd.com/content/7/S1/S6](http://www.ojrd.com/content/7/S1/S6).

[3]Eduard Ling, Raphael Zeltser and Victoria: A case of Cherubism with spondyloarthropathy. International Journal of Rheumatic Diseases. Volume 18, Issue 6, pages 681–684, July 2015.

[4]Surajit Bhattacharya and RK Mishra: Fibrous dysplasia and Cherubism. Indian J Plast Surg. 2015 Sep-Dec; 48(3): 236–248. doi: 10.4103/0970-0358.173101.

[5]Ernst J Reichenberger, Michael A Levine, Bjorn R Olsen, Maria E Papadaki<sup>4</sup>, Steven A Lietman: The role of SH3BP2 in the pathophysiology of Cherubism. Reichenberger et al. Orphanet Journal of Rare Diseases 2012, 7(Suppl 1):S5. <http://www.ojrd.com/content/7/S1/S5>.

[6]Ravi Prakash Sasankoti Mohan, Sankalp Verma, Udit Singh, Neha Agarwal: Cherubism Grades. Mohan RPS, et al. BMJ Case Rep 2013. doi:10.1136/bcr-2013-010366.

[7]Priya Singh, Abhinav Singh, M Srinivasa Raju: Cherubism: A case report. IJCRI 201 3; 4(5):260–265.  
[www.ijcasereportsandimages.com](http://www.ijcasereportsandimages.com).

[8]Yang Jiao, Mi Zhou, Yaowu Yang, Jun Zhou, and Xiaohong Duan: Cherubism misdiagnosed as giant cell tumor: a case report and review of literature. Int J Clin Exp Med. 2015; 8(3): 4656–4663. Published online 2015 March 15.

[9]Changing the Face of Cherubism. Pre clinical development of potential therapies for a rare and untreatable inflammatory bone condition. National Institute of Dental and Craniofacial Research. February 19, 2015.