

The Role of Serum Vitamin D Deficiency in oral Lichen Planus Case Control Study

Shaheen A Ahmed (BDS, MSc Oral Medicine , KBMS)¹

Abstract

Background: Lichen planus is an autoimmune chronic inflammatory condition of unknown etiology affecting stratified squamous epithelial. The cell-mediated immunity has a role in both developing oral lichen planus, and immune system regulation, that's why have role in the pathogenesis of oral lichen planus. The roles of vitamin D in an immune system and its anti-inflammatory effects have been indicated in recent study.

Objective: To determine the level of serum vitamin D in patients with oral lichen planus and in comparison with healthy subjects, and study the relation of serum vitamin D level with clinical types of oral lichen planus, symptom, and demography of oral lichen planus.

Patients and Methods: Two group were designed in this case –control study, the first consist of 40 patients with oral Lichen planus, while the second is control group which include 40 healthy people. A 5-ml blood sample was taken from patients and healthy subjects. The serum vitamin D levels were assessed with a vitamin D total (25-hydroxy vitamin D) kit by employing the electrochemiluminescence technique.

Results: Oral lichen planus mostly affect middle age female, the most common type of oral lichen planus was reticular type (95%) followed by erosive (57.5%) and atrophic oral lichen planus (45%). Mostly oral lichen planus appears on buccal mucosa bilaterally (95%). Vitamin D deficiency was higher in patient with oral lichen planus (60%) and (22.5%) in control group. The control group has more insufficient vitamin D level (22.5%) as compared to oral lichen planus patient(OLP) (15%), which was statistically significant. The mean of vitamin D level in serum of patients with oral lichen planus were 18.84 ± 12.69 ng/ml and in healthy subjects were 31.28 ± 13.58 ng/ml, that was statistically significant ($P < 0.001$).

Conclusion: The deficiency in serum vitamin D level was not only related to the development of oral lichen planus, but it was also related to the symptom, and types of oral lichen planus.

Keywords: Vitamin D deficiency, Lichen planus, Oral lichen planus, Autoimmune diseases.

Corresponding Author: shahenallany@yahoo.com

Received: 5th October 2019

Accepted: 4th November 2019

DOI: <https://doi.org/10.26505/DJM.17024991005>

¹ College of Dentistry - Hawler Medical University-Erbil-Iraq.

Introduction

Lichen planus (LP) is an autoimmune chronic inflammatory disease of the skin and mucous membrane, LP of the mucosa is regard a premalignant condition it is affects approximately 0.5–2% of the general population worldwide [1]. It is usually affects the individuals between the age between 3rd and 6th decade of life, and Asian population most commonly [2,3]. Female-male ratio of affliction is 3:2 and age of diagnosis of the lesions is 55 years(1). The percentage of the LP patients with the both skin and oral lesions is established from 50% to 70% [4]. The percentage of the patients present with oral lesions alone is 25%[5]. The clinical features of skin LP are purple, pruritic, polygonal papules with overlying reticular striations that especially on the extremities and lower back[6]. It also involves the scalp, nails, nasal, and other mucosa in the esophagus and genital area [6,7]. Clinically, reticular, erosive, atrophic, papular, plaque-like, and bullous types of OLP can be identified[6]. But practically most oral physician prefer 2 clinical designations: (1) reticular and (2) erosive. Reticular, plaque-like, and papular variants tend to be asymptomatic, while the erosive form is erythematous and usually symptomatic [7,8]. The OLP most commonly affect buccal mucosa bilaterally, in descending order of frequency the tongue, gingivae, alveolar ridge, lips, and less commonly the palate may also be affected [9,11]. Oral pigmentation has also been described in patients with lichen planus (lichen planus pigmentosus) [11]. Lichen

planus can result from melanin drop-out, especially in persons with pigmented skin[12].

The etiology of oral lichen planus (OLP) is unknown. Over the years, a large number of evidence has accumulated, indicating the immune system has a primary role in the development of OLP [1,13]. Histopathological features are infiltration of T lymphocytes as subepithelial band and destruction of basal cells, referred to as liquefaction degeneration, confirms this postulation [1]. These characteristics can be interpreted as the immune system cell-mediated pathway emergence the direct toxicity of T lymphocytes against the antigens exposed by the basal cell layer have a role in developing LP[13]. The immune system T lymphocytes might have an important role in initial and progression of OLP. These cells cannot have distinguished between the innate molecules of the body and foreign antigens. Activation of autoimmune T lymphocytes is a process that might move from oral mucosa to other parts of the body. It might even occur simultaneously with the initiation of mucosal lesions [1,13]. Study established the role of vitamin D in immune system regulation, responses, it inhibits proliferation of T helper cells, stimulates the regulatory effect of T cells, diminishes the B-lymphocyte differentiation, also inhibit immunoglobulin secretion [14].

Recent researches reported that the vitamin D has an endocrine effect on immune system cells, and have anti-inflammatory and regulate immune system(1). It has a potential

therapeutic benefit in autoimmune diseases, psoriasis, and neoplasms[15].The basic mechanisms of how vitamin D affects autoimmune diseases is not well elucidated, in some autoimmune diseases like lupus erythematosus, rheumatoid arthritis, multiple sclerosis, inflammatory diseases of the intestine, type I diabetes mellitus, Hashimoto, Graves diseases, and autoimmune gastritis vitamin D deficiency has been described[16].Researches on the effect of vitamin D levels in patients with Pemphigus Vulgaris (PV) showed that serum vitamin low in patients with PV compared to healthy subjects and this might exacerbate the disease through various immune system-related mechanisms [17].The results of the studies conducted by Marzano et al. [19,20] established the presence and possible effect of vitamin D deficiency in the pathogenesis of bullous mucocutaneous autoimmune diseases and PV.

A study on a patient with oral lichen palnus and vitamin D deficiency established improvement after vitamin D therapy reported by Varma et al [21]. Limited studies have been conducted on the role of vitamin D in pathogenesis of LP gave the importance of OLP as a premalignant condition and the possible role of immunologic factors in its etiology, and considering the effect of vitamin D on the immune system. There are many studies deal with the role of the vitamin D on autoimmune diseases. This study determined the level of serum vitamin D in patients with OLP and compare with healthy control subjects, also to determine the

relation of level of serum vitamin D with clinical types of OLP and symptom, and the demography of OLP.

Patients and Methods

This case- control clinical study was conducted Khanzad Teaching Center and Hawler Medical University /College of Dentistry. All the patients signed informed consent forms before being included in the study. No therapeutic intervention was made and the patients' data were kept confidential. No costs were inflicted on the patients for the laboratory tests. Consist of 40 patients with OLP considered as a study group, and 40 healthy from population with age and gender matched age and gender as a control group. Study and control groups were having similar nutritional habits and from the similar socio economic classes and from similar social classes and similar nutritional habits. The diagnosis of OLP based on the biopsy result. The inclusion criteria were affliction with OLP based on clinical views or clinical-pathological criteria[22,23].

Exclusion criteria of patients with amalgam restorations, with systemic disease like type I diabetes, renal and hepatic diseases, metabolic bone disease, patients with malignancy, malabsorption, patients on drugs like corticosteroid cytotoxic drugs ,anti-hypertensive drugs, anti-malarial ,and vitamin D supplement, multivitamin supplement or any drugs affecting bone metabolism (phenobarbital, or phenytoin) at least within 6 months were excluded,[24]thyroid or parathyroid disease, hyperparathyroidism, pregnant women

excluded [22]. After completion of informed consent forms, the demographic of the patients (age gender), general status of the patient, diseases duration clinical features (types of OLP, symptoms, association with pigmentation, skin lesions) were recorded. A 5-ml blood sample was taken from all the subjects and the serum vitamin D levels were determined with a vitamin D total (25-hydroxy vitamin D) kit using the electrochemiluminescence technique and then were compared with healthy subjects. The normal laboratory ranges of the serum vitamin D if lower than 20 ng /ml were regarded as vitamin D deficiency, if serum vitamin D level between 20-30 ng /ml were regarded as insufficient vitamin D, the serum vitamin D level between 30-100 ng/ml were considered as sufficient vitamin D, the level of vitamin D more than 100 ng/ml were considered as hyper- vitamin D [26].

Statistical analysis

The analysis of the data was done by using Statistical Package for Social Sciences (SPSS, version 22). Student's t- test of two independent samples was used to compare two means. Chi-square test of association was used to compare proportions. A p-value of ≤ 0.05 was considered to be statistically significant.

Results

The study group (cases) consist of 40 patients with oral lichen planus, in addition to 40 patients who served as a control group. The mean age + SD of the patients with OLP was 51.7 ± 10.8 years, and that of the controls was 49.2 ± 11.2 years ($p = 0.314$) as presented in Table (1). The table shows that the highest proportion (31.3%) of the sample aged 40-49 years, which was statistically not significant. The majority (75%) of the sample were females. Again no significant difference was detected between patients and controls regarding the gender distribution ($p = 0.606$).

Table (1): Age and gender of the study groups

	Patient		Control		Total		P
	No.	(%)	No.	(%)	No.	(%)	
Age (years)							
30-39	4	(10.0)	9	(22.5)	13	(16.3)	
40-49	13	(32.5)	12	(30.0)	25	(31.3)	
50-59	13	(32.5)	10	(25.0)	23	(28.8)	
≥ 60	10	(25.0)	9	(22.5)	19	(23.8)	0.492
Mean (+ SD)	51.7	(± 10.8)	49.2	(± 11.2)			0.314
Gender							
Male	9	(22.5)	11	(27.5)	20	(25.0)	
Female	31	(77.5)	29	(72.5)	60	(75.0)	0.606
Total	40	(100.0)	40	(100.0)	80	(100.0)	

It is evident in Table (2) that the majority of the patients (95%) had a reticular type of

OLP, then comes the erosive type (57.5%), and then the atrophic (45%). The other types

are presented in the table. The table shows that the majority (95%) of the lesions were located in the bilateral buccal mucosa, 47.5% were located on the tongue, and 22.5% were located in the gingiva. The skin lesion was

detected in 20% of patients with OLP. Pigmented lesions were detected in 20% of the patients, and in 62.5% of the patients, the lesion was symptomatic.

Table (2): Clinical features of OLP

	No.	(%)N = 40
Clinical presentation of OLP		
Atrophic	18	(45.0)
Reticular	38	(95.0)
Erosive	23	(57.5)
Papular	3	(7.5)
Bullous	3	(7.5)
Plaque	5	(12.5)
Mixed presentation	33	(82.5)
Oral site of the lesion		
Bilateral buccal mucosa	38	(95.0)
Gingiva	9	(22.5)
Labial mucosa	6	(15.0)
Floor of the mouth	4	(10.0)
Tongue	19	(47.5)
Palate	7	(17.5)
Lip	6	(15.0)
Skin lesions	8	(20.0)
Pigmentation of oral site	8	(20.0)
Symptomatic oral lesion	25	(62.5)

Table (3) shows that three-quarters of the patients had either vitamin D deficiency (60%) or insufficiency (15%), compared with

22.5% and 22.5% respectively among the controls ($p = 0.003$).

Table (3): Categories of vitamin D3 levels among cases and controls

D3 level	Patient		Control		Total		P
	No.	%	No.	%	No.	%	
Deficient	24	60.0	9	22.5	33	41.3	
Insufficient	6	15.0	9	22.5	15	18.8	
Sufficient	10	25.0	22	55.0	32	40.0	0.003
Total	40	100.0	40	100.0	80	100.0	

The mean of vitamin D among patients (18.84 ng/ml) was significantly less than the

mean (31.28 ng/ml) among the control group ($p < 0.001$) as presented in Figure (1).

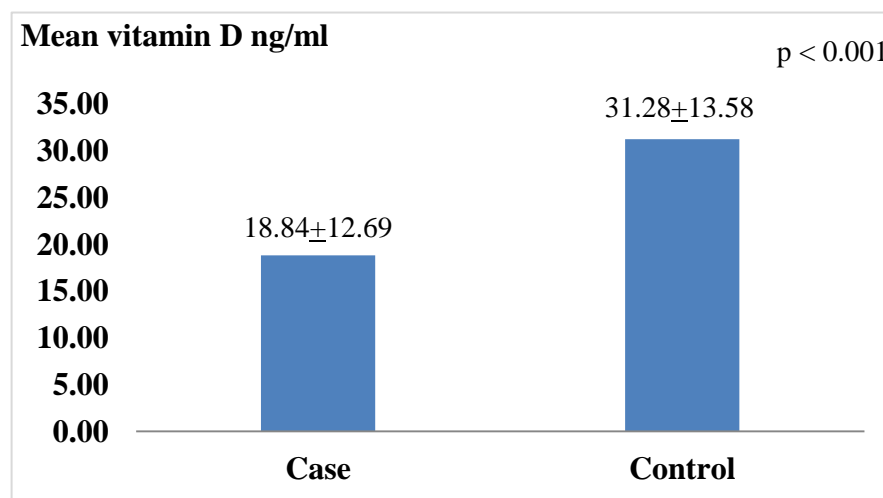


Figure (1): The means of vitamin D among patients and controls

Table (4) shows that the mean of serum vitamin D was 13.11 ng /ml among patients with atrophic lichen planus which was significantly less than the mean (23.53 ng/ml) among patients with no atrophic lesion (p = 0.006). The same can be applied for the erosive lesion where the mean was 14.42 ng/ml among those with such a lesion which was significantly less than the mean (24.82 ng/ml) among patients with no lesion

(p = 0.009). Regarding the other types of lichen planus, which was statistically no significant difference in the mean of vitamin D between those with and those without the mentioned lesions in Table(4). The table shows also that the mean vitamin D among symptomatic patients was significantly (p = 0.002) less than the mean among asymptomatic patients (13.24 vs 28.18 ng/ml respectively).

Table (4): Means of vitamin D by presence or absence of symptoms

	Clinical presentation				P
	Present		Absent		
	Mean of vitamin D (ng/ml)	(±SD)	Mean of vitamin D (ng/ml)	(±SD)	
Atrophic	13.11	(+7.64)	23.53	(+14.17)	0.006
Reticular	18.93	(+12.88)	17.15	(+11.81)	0.850
Erosive	14.42	(+9.57)	24.82	(+14.17)	0.009
Papular	15.29	(+11.01)	19.13	(+12.91)	0.621
Bullous	13.17	(+11.09)	19.30	(+12.84)	0.428
Plaque	21.14	(+21.42)	18.51	(+11.40)	0.671
Symptomatic	13.24	(+7.12)	28.18	(+14.58)	0.002

Discussion

In this study, there were many similarities and some dissimilarity in clinical features,

and demography of OLP with those reported previously. In general, the results of the present study about OLP are agree with other

studies done in China, South America, UK [9,11,27]. the OLP is more prevalent in third and fourth decade of life (mean of age was 51.7 years), which is a good agreement similar to other reports, [5,8] Spain (56.4years), UK (52.0 years), China (50.4 years), and Italy (56.7 years) [9,11,28,29]. The previous study reported that females more affected than males, [11] the same result was determined in the present study. Regarding types of OLP, the most common types of OLP were reticular and atrophic-erosive were reported similar results were reported by other studies [9,11,30,31] . On the other hand, the buccal mucosa bilaterally was the most common site of OLP, followed by the mucosa of the gingiva and the tongue [9,11,28,29,32,33,34,35]. Multiple oral sites involvement was also common, patients with more than one oral sites was reported in buccal mucosa concomitant gingiva. Single lesion on the gingiva, palate and floor of the mouth was rare, whereas these site were involved in concomitant with other site like buccal mucosa or tongue, or the lesions of OLP affect multiple oral sites.

Skin lesions of lichen planus appear before, or arise at the same time with OLP or appear after the development of OLP and it is documented that 20-34% of the patients with OLP had also skin LP [11]. In this study, 20% of patients had a history skin LP higher than done by Pakfetrat et al (15.5%) [36]. This to be a good reason for Oral and Maxillofacial Medicine specialist to examine the skin of the hands, feet and legs of patients attending oral medicine clinic to diagnosis,

skin and oral lichen planus, when relevant, refer the patient to dermatologist.

Regarding pigmentation in this study 8 patients with OLP had also pigmentation (pigmentation associated with OLP). The most common site of pigmentation was buccal mucosa, followed by gingiva, lateral and dorsal surface of the tongue and hard palate, the nature of pigmentation was diffuse or in a patches, brown to black in color. The same result was reported by other studies [37]. In this study most of the patients (62.5 %) complained of symptom (burning sensation, pain, or soreness) similar result was established by other research [11]. The epidemiological study reported the association between vitamin D deficiency and an increased incidence of autoimmune diseases. The hypothesis of vitamin D deficiency as a contributing factor in lichen planus supported by the study done by Van Belle et al [38]. Which is he review the role of serum vitamin D in autoimmune diseases like rheumatoid arthritis, systemic lupus erythematosus, type 1 diabetes mellitus, inflammatory bowel diseases, multiple sclerosis, asthma and in infectious diseases.

The serum vitamin D level was estimated in patients with OLP group and in the control group. The results show statistically significant difference in serum vitamin D levels between the two groups the deficiency was found in 60% of the patient with OLP compared with 22.5% of control group, while the insufficient vitamin D was higher in control 22.5% as compared to OLP group 15%, other study reported the deficiency in

serum vitamin D was more common in OLP cases (70.6%) when compared with control group (34.3%) , but insufficient serum vitamin D was more common in control group (35.3)when compared with OLP group (16.7%) [39]. Concerning patients who had erosive, and atrophic types of lichen planus which were associated with oral symptom (burning sensation, pain or soreness) had also vitamin D deficiency, and had more symptoms than the OLP patients who had insufficient, and sufficient vitamin D. This results indicate that there is a correlation between the vitamin D deficiency or serum vitamin D level and the types OLP and oral symptoms of LP similar result was established by the other study [23].

Conclusions

The deficiency in serum vitamin D level was not only related to the development of oral lichen planus, but it was also related to the symptom, and types of oral lichen planus.

Recommendations

Recommendation it is better to do other study OLP and vitamin D level and any patient with vitamin D deficiency giving supplements with vitamin D and follow up the patient to see improvement.

References

- [1]Glick M. Burket's Oral Medicine. 12th ed. People's Medical Publishing House: USA; 2015; 104-108.
- [2]Alam F, Hamburger J. Oral mucosal lichen planus in children. *Int J Paediatr Dent.* 2001; 11:209–14.
- [3]Laeijendecker R, Van Joost T, Tank B, Oranje AP, Neumann HA. Oral lichen planus in childhood. *Pediatr Dermatol.* 2005; 22:299–304.
- [4]Handa S, Sahoo B. Childhood lichen planus: a study of 87 cases. *Int J Dermatol.* 2002; 41:423–7.
- [5]Kumar V, Garg BR, Baruah MC, Vasireddi SS. Childhood lichen planus (LP). *J Dermatol.* 1993; 20 :175–7.
- [6]Scully C, Beyli M, Ferreiro MC, Ficarra G, Gilly, Griffiths M, et al. Update on oral lichen planus: etiopathogenesis and management. *Crit Rev Oral Biol Med.* 1998; 9: 86-122.
- [7]Eisen D, Carozzo M, Bagan Sebastian JV, Thongprasom K. Number V. Oral lichen planus: clinical features and management. *Oral Dis.* 2005; 11:338-49.
- [8]Morrish NJ, Wang SL, Stevens LK, Fuller JH, Keen H: Mortality and causes of death in the WHO Multinational Study of Vascular Disease in Diabetes. *Diabetologia* 2001; 44: S14– S21.
- [9]Xue JL, Fan MW, Wang SZ, Chen XM, Li Y, Wang L: A clinical study of 674 patients with oral lichen planus in China. *J Oral Pathol Med.* 2005; 34: 467-72.
- [10]Eisen D: The clinical features, malignant potential, and systemic associations of oral lichen planus: a study of 723 patients. *J Am Acad Dermatol.* 2002; 46: 207-14.
- [11]Ingafou M, Leao JC, Porter SR, Scully C: Oral lichen planus: a retrospective study of 690 British patients. *Oral Dis.* 2006;12: 463-8.
- [12]Scully C (2013). Oral and maxillofacial medicine; the basis of diagnosis and

- treatment. 3rd. ed. London, UK: Elsevier Ltd. P. 138.
- [13]Nevilie BW, Dammo DD, Allen CM, Boqout JEM. Oral and maxillofacial pathology. 3rd ed. Elsevier Inc: St Louis; 2009; 360-368.
- [14]Faezi S T, Ansari N, Paragomi P, Akhlaghi M, Ghanavat M, Davatchi F. (2014) Vitamin D deficiency in patients with Behcet's disease. J Diabetes Metab Disord.13(1):18.
- [15]D'Aurizio F, Villalta D, Metus P, Doretto P, Tozzoli R. Is vitamin D a player or not in the pathophysiology of autoimmune thyroid diseases? Autoimmun Rev. 2015; 14: 363-369.
- [16]Kriegel MA, Manson JE, Costenbader KH. Does vitamin D affect risk of developing autoimmune disease? A systematic review. Semin Arthritis Rheum. 2011; 40: 512- 531.
- [17]El-Komy MH, Samir N, Shaker OG. Estimation of vitamin D levels in patients with pemphigus Vulgaris. J Eur Acad Dermatol Venereol. 2014; 28: 859-863.
- [18]Joshi N, Minz RW, Anand S, Parmar NV, Kanwar AJ. Vitamin D deficiency and lower TGF- β /IL-17 ratio in a North Indian cohort of pemphigus vulgaris. BMC Res Notes. 2014; 7: 536.
- [19]Marzano AV, Trevisan V, Eller-Vainicher C, Cairoli E, Marchese L, Morelli V, et al. Evidence for vitamin D deficiency and increased prevalence of fractures in autoimmune bullous skin diseases. Br J Dermatol. 2012; 167: 688-691.
- [20]Marzano AV, Trevisan V, Cairoli E, Eller-Vainicher C, Morelli V, Spada A, et al. Vitamin D and skeletal health in autoimmune bullous skin diseases: a case-control study. Orphanet J Rare Dis. 2015; 10: 8.
- [21] Varma RB, Valappila NJ, Pai A, Saddu SC, Mathew N. Oral Lichen Planus: Is Vitamin D Deficiency a Predisposing Factor? A Case Report. Int J Sci Stud. 2014; 2: 230-232.
- [22]Ravi Prakash S M, Ghanta S, Verma S, Agarwal N, Gupta N, Singh U. Meteorological influences on the incidence of lichen planus in a north Indian population. J Oral Sci.2013; 55:311-18.
- [23]Gupta A, Mohan RPS, Gupta S, Malik S, Goel S, Kamarthi N. Roles of serum uric acid, prolactin levels, and psychosocial factors in oral lichen planus. J Oral Sci. 2017; 59 (1):139-146.
- [24]Faezi S T, Ansari N, Paragomi P, Akhlaghi M, Ghanavat M, Davatchi F. Vitamin D deficiency in patients with Behcet's disease. J Diabetes Metab Disord. 2014;13(1):18.
- [25]Bakhtaran M, Haghghi A, Arabi M, Loghman M. Investigating the Levels of Serum Vitamin D in Patients with Rheumatoid Arthritis Referred To Rasoul-Akram Hospital During 2011-2012. IJMS. 2014;39(5):476-9.
- [26] Ibrahim M H, Alloush T K, Rahim M K A. Vitamin D Level in Multiple Sclerosis Patients. Could Vitamin D Level Be Routine Investigation for Multiple Sclerosis Patients? Neurosci Med. 2014; 5:201-4.

- [27] Arisawa EA, Almeida JD, Carvalho YR, Cabral LA. Clinico- pathological analysis of oral mucous autoimmune disease: A 27-year study. *Med Oral Patol Oral Cir Bucal*. 2008;13: E94-7.
- [28] Gandolfo S, Richiardi L, Carrozzo M, Broccoletti R, Carbone M, Pagano M, et al. Risk of oral squamous cell carcinoma in 402 patients with oral lichen planus: A follow-up study in an Italian population. *Oral Oncol*. 2004; 40:77–83.
- [29] Bermejo-Fenoll A, Sánchez-Siles M, López-Jornet P, Camacho-Alonso F, Salazar-Sánchez N. A retrospective clinicopathological study of 550 patients with oral lichen planus in south-eastern Spain. *J Oral Pathol Med*. 2010; 39:491–6.
- [30] Myers SL, Rhodus NL, Parsons HM, Hodges JS, Kaimal S. A retrospective survey of oral lichenoid lesions: revisiting the diagnostic process for oral lichen planus. *Oral Surg Oral Med Oral Pathol Oral Radiol Endod*. 2002; 93:676-81.
- [31] Machado AC, Sugaya NN, Migliari DA, Matthews RW. Oral lichen planus. Clinical aspects, and management in fifty-two Brazilian patients. *West Indian Med J*. 2003; 52:203-7.
- [32] Carbone M, Arduino PG, Carrozzo M, Gandolfo S, Argiolas MR, Bertolusso G, et al. Course of oral lichen planus: A retrospective study of 808 northern Italian patients. *Oral Dis*. 2009; 15:235–43.
- [33] Edwards PC, Kelsch R. Oral lichen planus: Clinical presentation and management. *J Can Dent Assoc*. 2002; 68:494–9.
- [34] Shi P, Liu W, Zhou ZT, He QB, Jiang WW. Podoplanin and ABCG2: Malignant transformation risk markers for oral lichen planus. *Cancer Epidemiol Biomarkers Prev*. 2010; 19:844–9.
- [35] Van der Meij EH, Schepman KP, van der Waal I. The possible premalignant character of oral lichen planus and oral lichenoid lesions: A prospective study. *Oral Surg Oral Med Oral Pathol Oral Radiol Endod*. 2003; 96:164–71.
- [36] Pakfetrat A, Javadzadeh-Bolouri A, Basir-Shabestari S, Falaki F. Oral Lichen Planus: A retrospective study of 420 Iranian patients. *Med Oral Patol Oral Cir Bucal*. 2009 Jul 1;14 (7): E315-8.
- [37] Chainani-Wu N, Silverman S, Jr, Lozada-Nur F, Mayer P, Watson JJ. Oral lichen planus: Patient profile, disease progression and treatment responses. *J Am Dent Assoc*. 2001; 132 : 901–9.
- [38] Van Belle TL, Gysemans C, Mathieu C. Vitamin D in autoimmune, infectious and allergic diseases: A vital player? *Best Pract Res Clin Endocrinol Metab* 2011; 25: 617-32.
- [39] Gupta A, Sasankoti Mohan RP, Kamarthi N, Malik S, Goel S, Gupta S. Serum Vitamin D Level in Oral Lichen Planus Patients of North India- A Case-Control Study. *Journal of Dermatological Research and Therapy*. 2017; 17-148.