

## Minimal Surgical Interference with Depomedrol Injection Used to Treated Unicameral Bone Cyst

Ahmed K Jameel (MSc)<sup>1</sup>

### Abstract

**Background:** Simple bone cyst or UCB is a benign tumor of bone mostly in children and young adult treated by different approach. (SBC or UBC) are predilection for the metaphyseal region of the long bones. Our study is to treat UCB cyst by minimal surgical interference with depomedrol injection.

**Objective:** To study the effect of curettage and depomedrol injection in healing of UCB CYST in short period of time with least morbidity of the patient.

**Patients and Methods:** Twenty four patients their age between 8 to 30 years (23 cases of long bone including 13 upper humerus and 10 femur), one case is in calcaneus bone treated under GA under fluoroscopic technique and depomedrol injection in local.

**Results:** In 6-8 weeks follow up of the patient after our procedure the processes of healing of UCB cyst almost fully in most of the cases, the successful rate was 98-100% in most of the cases in both clinical picture and radiological picture

**Conclusion:** Find from this study that UCB cyst can be treated successfully by this procedure whatever the age of the patient and the size of the cyst and location.

**Keywords:** Simple bone cyst, unicameral bone cyst, mini approach in surgery, Depomedrol

**Corresponding Author:** alazzawia57@yahoo.com

**Received:** 27<sup>th</sup> January 2019

**Accepted:** 12<sup>th</sup> March 2019

---

<sup>1</sup> Department of orthopedic surgery- College of Medicine-University of Mousel - Iraq.

### Introduction

Simple and unicameral bone cyst (SBC and UBC) are predilection for the metaphyseal region of the long bones. They found especially in the femoral neck, proximal humerus. Also found in the flat bones and spine [1]. SBC is a fluid lesion filled with fibrous. SBC occurs in 51% proximal humerus[2]. Bone cystic lesion especially is a solid component is predominant, this is like tumor or might conduct as a bone tumor. The both SBC and

UBC consider tumor in undefined neoplastic nature category in the WHO organization 2013 [3]. The treatment of SBC and UBC was included observation, percutaneous steroid injection and the last choice surgery. The causative of the lesion is unknown and may be formed from accumulation of interstitial fluid result from defect in lymphatic or venous discharge of the bone [4]. A successful treatment should give a higher healing rate, short time to unite and no

recurrence. Minimally invasive technique preserves periosteum, muscles, and blood supply. With curettage cyst decompression and use of allogeneic bone graft, the technique has easy and effective approach these cysts are sometimes classified as either active or latent. In this cases used mini approach in surgery, curtain and injection of depomedrol to be treated the SBC.

### **Patients and Methods**

Twenty four patients their age between 8 to 30 years (23 cases of long bone including 13 upper humerus and 10 femur), one case is in calcaneus bone treated under GA under fluoroscopic technique and depomedrol injection in local.

Examination some patients have tenderness and mild swelling. Plain radiographs showed cyst of radilocent on CT-scan with filled of fluid in the calcaneus, femur and humerus not breaching the cortex. Laboratory evaluation including complete blood count, CRP, ESR, serum electrolyte (calcium and phosphate), serum albumin and globulin, renal function test, hepatic function test, urinalysis and parathyroid hormones.

Surgical technique: The patients were planned for percutaneous cyst curettage. The patients were taken in supine position under general anesthesia. A small longitudinal skin incision 1.5 cm is made and fenestration was created in outer cortex of the cyst with 3.2 mm drill bit percutaneous under the guidance of image intensifier. An infant feeding tube

was inserted to aspirate out the content of the cyst which were sent for tissue analysis, a small curette was introduced and copious curtain of the bone cyst was carried out, serosanguinous material content of cyst aspirated and collected through suction catheter decompress the cyst. Finally was injected depomedrol (80 mg) inside the cavity under image intensifier guidance under general anesthesia.

### **Statistical analysis**

Analysis of data was done by using descriptive methods.

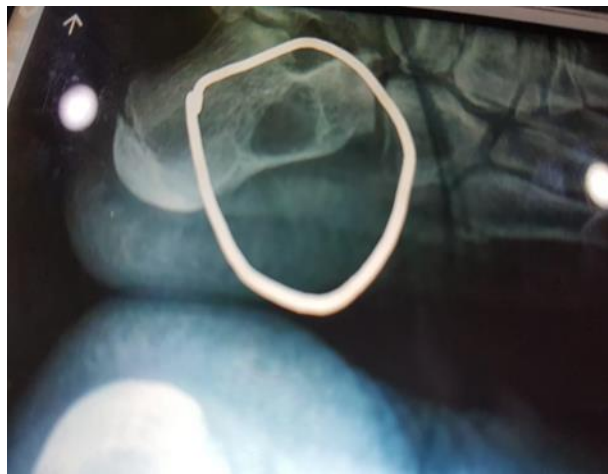### **Results**

This study was included 24 patients (16 male and 8 female) with age range from 8-30 years old. The SBC cases were divided according region to Table (1): 1 case in calcaneus (figure1), 10 cases in femur (figure 2 & 3), and 13 cases in humerus. All Laboratory evaluation test were within normal value (including complete blood count, CRP, ESR, serum electrolyte (calcium and phosphate), serum albumin and globulin, renal function test, hepatic function test, urinalysis and parathyroid hormones).

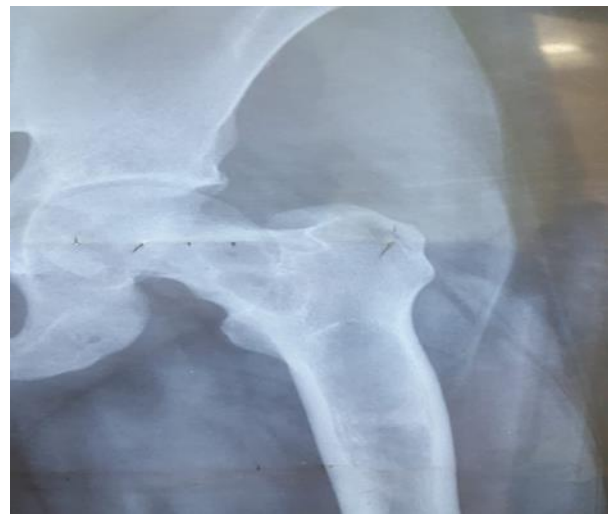Healing time for UBC cases was take (6 – 8) weeks, the full functional recovery was happen within two months after surgery (case in calcaneus after surgery Figure (4)). The complication is very few, except pain at the site of operation, no infection, and no fraction.

**Table (1):** Distribution of Unicameral bone cyst according to site.

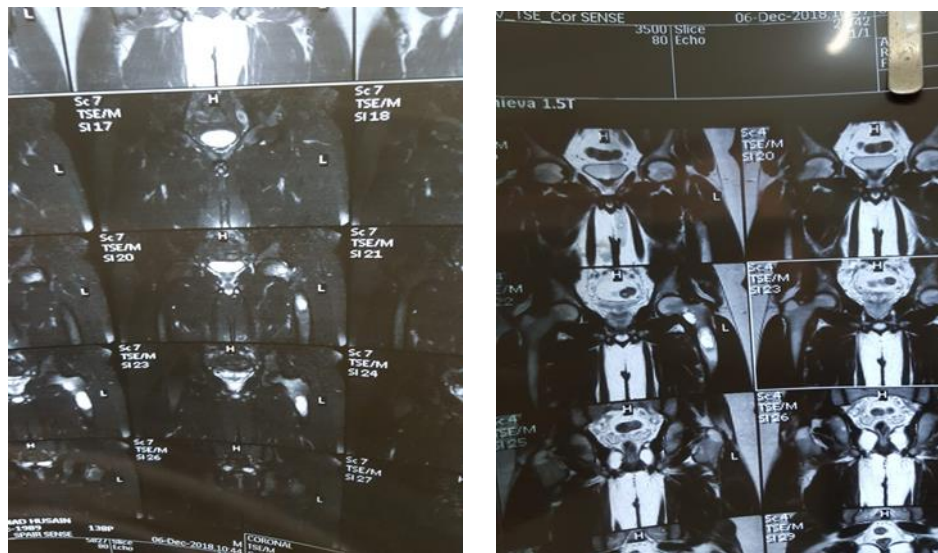
Unicameral bone cyst/site	Number
calcaneus	1
Femur	10
Humerus	13
Total	24



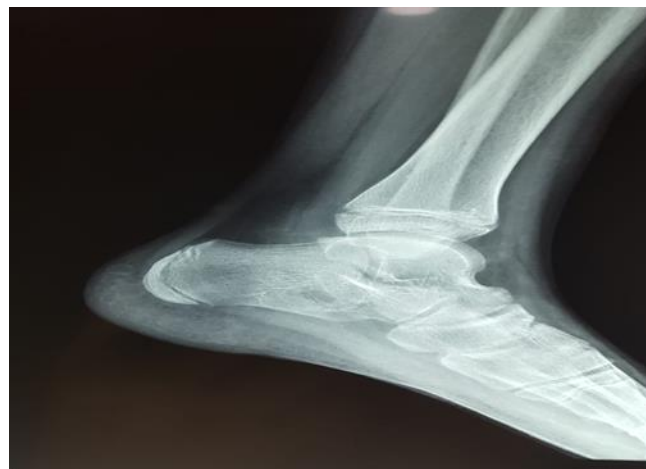**Figure (1):** Pre-operative X-ray of unicameral bone cyst in calcaneus.



**Figure (2):** Unicameral bone cyst in the femur neck and subtrochanteric area in the mature patient.



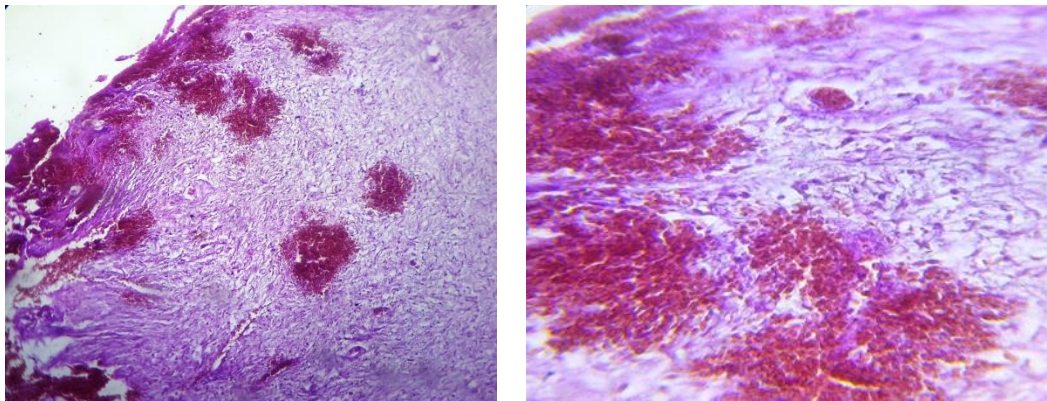
**Figure (3):** MRI of unicameral bone cyst in the femur neck and subtrochanteric area in the mature patient.



**Figure (4):** Post – operative X – ray, 45 days after treatment.

The result of histopathological examination of UBC biopsy was confirmed the cyst to be SBC by appear the area have fibrous membrane, spindle cells and occasional cells.

The connective tissue with prominent vasculature, hemosiderin, cholesterol clefts and the bone was surrounding may be with irregular cement lines Figure (5).



**Figure (5):** Histopathological examination of the cyst. The result was show the connective tissue with prominent vasculature, hemosiderin, cholesterol clefts and the bone was surrounding may be with irregular cement lines. (H&E stain 10X,40X).

## Discussion

SBCs presented 3% of primary bone tumors and remain generally cause of pathological break ans metaphysis in the long bones, essential the proximal humers and proximal femur (5,6). The UBC is most common benign tumor of the calcaneus (7). UBC is more frequently in man (8), this also found in this study . The histopathological examination result was appear there cyst region have the inflammation properties and found connective tissue with prominent vasculature, hemosiderin, cholesterol clefts and the bone was surrounding may be with irregular cement lines. This is the same as described in previous study revealed that the connective tissue of simple cyst bone have dense inflamed connective tissue stroma with extravasated red blood cell, necrotic change and chronic inflammatory cells (9).

In the Cases those included in this study recommended surgical (interference) for treatment because lead to risk of fracture bone that. The cyst lessens the bone

properties in bearing the weight. The treatment used in this study minimal surgical interference with depomedrol at the same time give excellence result within limited time and decrease risk for the patient. The surgery is very limited by less than one centimeter opening in the cortex of cyst under mask anesthesia and treated by small curat and suturing the wound and injection by depomedrol 80 mg non weight bearing for four weeks and then partials weight bearing for two weeks. The last x ray is after 45 days and patient be cure, no pain and able to full bearing and all patients recover excellent with very few complication.

## Conclusions

The result of this study was confirming the patient with Simple cyst bone be better and recover faster by applying to mini approach in surgery, curtain and injection of depomedrol.

## References

- [1] Enneking WF(1983). Tumor-like lesions. In : Musculoskeletal Tumor Surgery. 1st edition, vol. 2. Churchill Livingstone, New York, pp 1492-1513.
- [2] Spence KF, Sell KW, Brown RH(1969). Solitary bone cyst: treatment with freeze-dried cancellous bone allograft. A study of one hundred seventy-seven cases. J Bone Joint Surg Am;51:87-96.
- [3] Fletcher DM, Bridge JA, Hogendoorn PCW, Mertens F(2013). WHO classification of tumors of soft tissue and bone. Lyon: IARC.
- [4] Kar Hao Teoh, Adam C Watts, Yu-Han Chee, Robin Reid, Daniel Edward Porter(2010). Predictive factors for recurrence of simple bone cyst of the proximal humerus. Journal of Orthopaedic Surgery;18(2):215-9.
- [5] Bensahel H, Jehanno P, Desgrippes Y, Pennecot GF(1998). Solitary bone cyst: controversies and treatment. J Pediatr Orthop B.;7:257-61.
- [6] Gündeş H, Sahin M, Alici T(2010). Unicameral bone cyst of the lunate in an adult : case report. J Orthop Surg Res ; 5 :79.
- [7] Ly JQ, LaGatta LM, Beall DP(2004). Calcaneal chondroblastoma with secondary aneurysmal bone cyst. AJR Am J Roentgenol ; 182 : 130.
- [8] Javdan M, Zarezadeh A, Gaulke R, Eshaghi MA, Shemshaki H(2012). Unicameral bone cyst of the scaphoid : a report of two cases. J Orthop Surg (Hong Kong); 20 :239-242.
- [9] Joy, E. T., Raghupathy, L. P., Sherubin, J. E., & Kiran, M. S. (2015). A rare presentation of a simple bone cyst. Journal of pharmacy & bioallied sciences, 7(Suppl 2), S823-6.