


Histological and Histomorphometrical Evaluation of Rabbit Oral Cavity Wound Healing by Feeding Absorbable Amino Acid

Manar Abd Alrazaq Hassan  ¹

¹University of Diyala, college of dentistry, Diyala, Iraq.

Abstract

Background: Traumatic oral ulcer is well-circumscribed, depressed lesion with an epithelial defect that is covered by a fibrin clot, resulting in a yellow-white appearance, occurs due to chemical, mechanical or thermal injury to oral mucosal end with painful erosion. Amino acids are necessary for wound healing because they promote the growth of connective tissue as well as the activation and proliferation of fibroblasts.

Objective: evaluation the effect of systemic application of amino acid collection (oral intake) in treatment of traumatic oral ulceration over selected time by histological and histomorphometric assessment of soft tissue healing.

Patients and Methods: 20 adult male rabbits that weight about 700-900 Kg and age about (6-8) months where used in this experimental study. The traumatic ulcer created with (8mm) diameter, and (1mm) by surgical round diamond bur in the right cheek mucosa, then divided the groups in two groups, 10 rabbits for control group that left healed normally, and 10 rabbits for experimental group that daily used mixture of amino acids systemically through mixing with water for one month. The animals were sacrificed along 3 and 7 days healing periods and the species examined histologically after histological preparation of the traumatic ulcer.

Results: Histological and histomorphometric findings showed decreased inflammation, accelerated reepithelization of ulcer surface, better angiogenesis, and promoted remodeling of the extracellular matrix resulting with enhanced tissue maturation and complete healing in all study groups than in the control group.

Conclusion: the chemical medicament that represented by systemic application of amino acid effective in accelerating the healing of traumatized ulcers in experimental group than that in control group by accelerated cell proliferation and mucosa reepithelization.

Keywords: Traumatic ulcers, amino acid, reepithelization.

Correspondence: Manar Abd Alrazaq Hassan

Email: manar@uodiyala.edu.iq

Copyright: ©Authors, 2024, College of Medicine, University of Diyala. This is an open access article under the [CC BY 4.0](http://creativecommons.org/licenses/by/4.0/) license (<http://creativecommons.org/licenses/by/4.0/>)

Website:

<https://djm.uodiyala.edu.iq/index.php/djm>

Received: 27 March 2024

Accepted: 13 June 2024

Published: 25 December 2024

Introduction

The mucous membrane lining the interior of the mouth is called the oral mucosa. It consists of a layer of stratified squamous epithelium known as "oral epithelium" and the lamina propria, a connective tissue beneath it (1). The mouth cavity has occasionally been seen as a mirror that reflects a person's overall health (2). The oral mucosa, which lines the inside of

the mouth, can change to indicate systemic disorders like diabetes or vitamin deficiencies, as well as the local impacts of long-term alcohol or tobacco use (3). When compared to the skin, the oral mucosa often heals more quickly and leaves fewer scars behind (4,5, 6). According to histology and function, the oral mucosa can be categorized into three primary groups: Lining mucosa, which is non-keratinized; the alveolar mucosa, which lines the space between the buccal and labial mucosae (7, 8). Ocular epithelial cells are frequently replaced by cells every 14 to 21 days (9). This is because there is a continuous turnover due to the high functional demands placed on the mouth cavity (10,11). The oral epithelium was specialized cells referred to as non-keratinocyte cells in addition to keratinocytes cells, which include melanocytes, Langerhan cells, and Merkel cells. (12-13). Dendritic cells obtained from the bone marrow, known as Langerhans cells, settle in the stratum spinosum. The function of these cells is phagocytosis in the epithelium (14-15,16). Langerhans cells serve as the connecting factor between the immune system and the oral mucosa (17,18). In addition to fibroblasts, macrophages, mast cells, and inflammatory cell fibers, which is present as the lamina propria. The epithelium consists of the superficial papillary layer and the deeper reticular layer (19,20). Because of their strong bond with the bone, these fibrous attachments, known as mucoperiosteum, give the oral mucosa the ability to withstand compression and shear (21). The fibroblast is the main cell type that performs vital tasks in the lamina propria. It takes part in the synthesis and replenishment of the amorphous substance and connective fibers, as well as in the process

of wound healing, when an increase in fibroblasts occurs (22). The function of mucosa represented by Protective Function: The mechanical, chemical and biological stressors of daily life continuously test the mouth cavity's environment (6). Nonetheless, new research indicates that it might be related to immunity (23, 24). To diagnose the oral epithelial should use tissue preparation Once properly prepared, an oral mucosa biopsy sample may be examined under a microscope. Specimen preparation techniques include suitable dehydration and tissue preservation, cleaning, paraffin infiltration, sectioning, and staining—most frequently with hematoxylin and eosin (H&E) (25-26). Organic substances have both amino and carboxylic acid functional groups are known as amino acids (27). Despite the fact that nature contains more than 500 amino acids (28). The amino acids arginine, cysteine, glutamine, tyrosine, glycine, proline, and serine are among those that are conditionally necessary for oral health (29). A-aminoglutaric acid is glutamate. One amino acid that is needed to make proteins is glutamic acid. It transforms into glutamate throughout the body. This substance facilitates the transmission and reception of information between brain nerve cells (30). It is important for Brain Functioning by providing the brain with the high energy needed for great functioning and boosting mental preparedness (31). Heart Function: One type of glutamic acid that helps to improve cardiac function is monosodium glutamate. It also lessens the discomfort in the chest brought on by coronary heart disease. Prostate Health: Glutamic acid supports the prostate's regular operation. Glutamic acid is naturally present in large concentrations in the prostate.

Immune system support and detoxification: The elimination of harmful metabolic waste products generated by the human body depends on glutamic acid (31). Aspartic acid aminosuccinic acid produced when proteins are hydrolyzed is aspartic acid. According to certain athletes, aspartic acid increases stamina. Your immune system strengthened by it. (32,33). The development of neural tissue and neurotransmission involves the production of proteins, asparagine, arginine, nucleotides, and various other chemicals, all of which are mediated by L-asp. Leucine, isoleucine, and valine are among the branched-chain amino acids (BCAAs), which are vital nutrients. Dairy products, beef, and legumes all contain them. BCAAs may lessen muscle breakdown by promoting the production of new muscular tissue (34,35,36) In conclusion, it appears that a dietary approach centered on BCAA supplementation that aims to lessen or avoid muscle damage brought on by intense exercise is not very effective (37). A semi-essential amino acid that called L-arginine essential for smooth muscle cell relaxation and blood pressure reduction (38) According to the meta-analyses L-arginine helps hypertensive adults reduce their systolic and diastolic blood pressure in a

meaningful way, lowering the diastolic blood pressure of expectant mothers with gestational hypertension and shortening surgical patients' hospital stays; two of the three meta-analyses revealed a 40% decrease in the frequency of hospital-acquired infections (39).

Patients and Methods

Study design and protocol: The experiment was done at Diyala province- Baqubah from 1st November 2023, and all parts of the work (surgical and histological work and writing the paper) on 1st March 2024. The 20 male rabbits were randomly assigned and used in the work into two groups consisting of 10 animals each: the experimental group and the control group. Each group was divided into two groups according to healing periods to 3 days and 7-day healing intervals (5 rabbits to each interval). The intramuscular (IM) injection of xylazine 2% (0.08 ml/kg B.W.) and ketamine 10% (3 mg/kg B.W.) was used to provide the general anesthetic solution. All surgical tools and towels were autoclaved for 30 minutes at 121°C and 15 bar/cm² of pressure prior to the procedure as found in Figure 1.

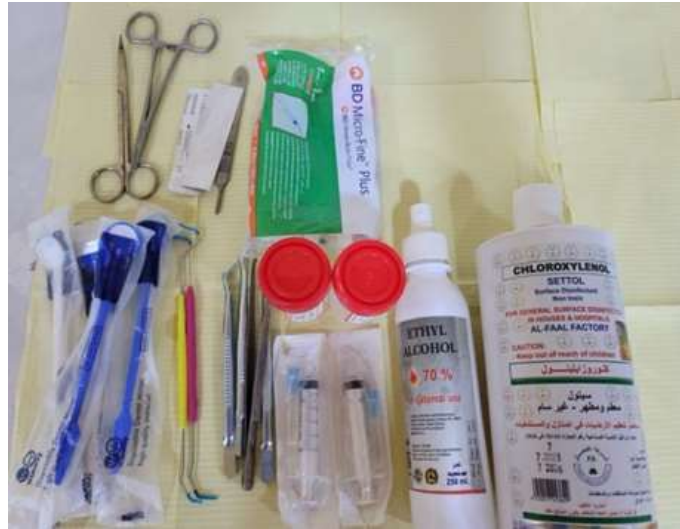

Figure (1): surgical instruments.

A bur stopper was put on the surgical bur once the necessary ulcer size was ascertained using the digital vernia. Using a round diamond bur at 15,000 revolutions per minute (rpm), an 8

mm traumatic ulcer was created on the mucosa of the right cheek as found in Figure 2.

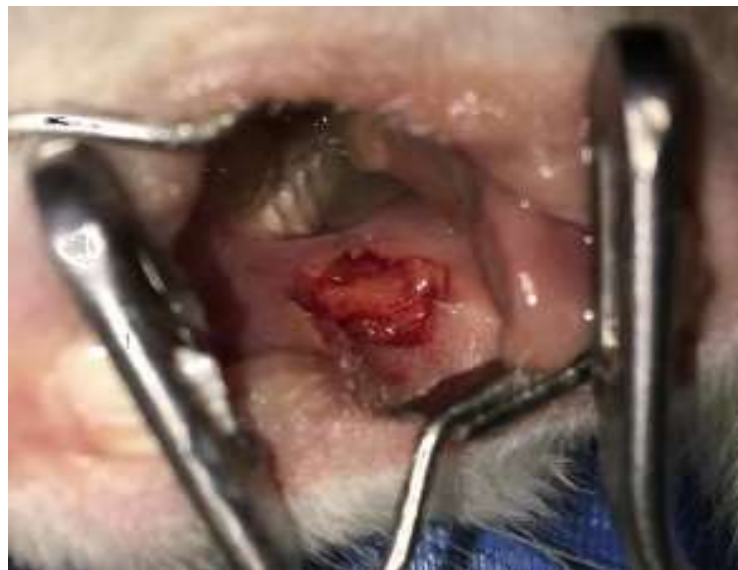

Figure (2): trumatic ulcer.

Ten milliliters of sterile distilled water were administered as a single dosage once a day to treat the ulcer (Control Group). An amino acid (40) single dosage of 0.3 g/kg/day was used to treat the ulcer. Animals were killed with an excess of general anesthesia at the conclusion of the three and seven-day healing periods after ulceration in order to obtain ulcer samples for histological and histochemical analysis. In order to create slides, the specimens were embedded in paraffin, fixed in 10% formalin solution, and sectioned into thin 5 m slices. Hematoxylin and eosin (H&E) staining was done under a light microscope for histological evaluation (41, 42).

Statistical Analysis: Data analysis from clinical and microscopically investigated studies was conducted in the current study using the computer statistical program SPSS (statistical package of social science software, version 23). The statistical analysis was used:

1. Descriptive Data Analysis includes Mean, Standard Deviation, and Standard Error.
2. Inferential Data Analysis -Independent T-test for comparison between the control and study groups and between two different variables of the same group and ANOVA test to show the significant differences between different groups in all durations and between different durations of each group of the variables to be measured. The level of significance was used in statistics as Highly significant at $P < 0.001$, Significant at $P < 0.05$, and non-significant at $P > 0.05$ (43).

Results

All rabbits recovered clinically after induced ulceration in buccal mucosa without complications or interference with normal daily activities, with no changes in body weight of the rabbits at all healing periods. In

all study groups, After the third day of ulceration, the ulcers were noticeably smaller in diameter, did not produce any exudate, had uneven borders, and had shallow depths that were covered in yellow or white pseudomembrane. On the seventh day, the ulcers had lessened in size, with a white halo surrounding them and a slight redness. However, in control, the ulcer on the 3rd day formed with bleeding and exudate formation with minimal reduction of ulcer diameters and size. On the seventh day, the ulcer had clearly shrunk in size, and there was redness surrounding the wounded area, encircled by a white halo.

Histological Finding

histologically, on the third day, the keratinocytes in the study groups demonstrated active epithelial growth moving toward the core defect from the ulcer's edge, accompanied by a noticeable decrease in the ulcer area due to the approximate proximity of two ulcer margins. A study group's moderate infiltration of inflammatory cells, a large number of blood vessels, a profusion of fibroblast cells, and the presence of new collagen fibrils dispersed randomly across all study groups were all revealed by the lamina propria, which also displayed early immature granulation tissue formation with inflammatory cell infiltration figure 3. Upon light microscope examination, the third control group revealed limited epithelium regeneration from the ulcer margin toward the central defect. Additionally the lamina propria show heavy infiltration of both acute and chronic inflammatory cells in the central area of the ulcer, which was associated with necrotic tissue. Few fibroblast cells were also

visible, along with sparse and thin blood vessels below the necrotic area (see figure 4) At 7th day the histological picture of the ulcer of the study group show new well-defined keratinized squamous epithelium with well-defined rete ridge. Closed approximation at wound edges with strong epithelial activity and high maturity of epithelial cell layers in all study groups (Figure 5). Lamina propria showed transition of mature granulation tissue into fibrotic connective tissue in all study groups that characterized by signs of collagen

fibers remodeling, copious amount of numerous blood vessels, increase of fibroblast cells number and reduction in the inflammatory cells infiltration (absent of inflammatory cells in study group) while the histological picture of control group reveal the lamina propria, which has recently developed thin epithelium in the ulcer region, with granulation tissue development, a moderate to severe amount of inflammatory cells, few blood vessels, and few collagen fibers (Figure 6).

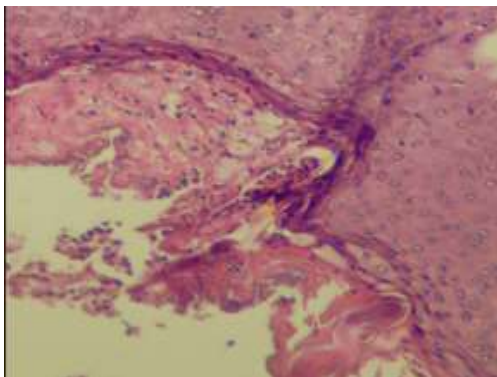


Figure (3): The study group on the 3rd day showed inflammatory cell proliferation and collagen fiber H&E stained slide (x10).

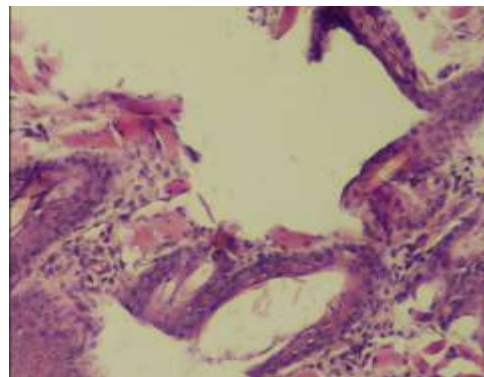


Figure (4): The control group on 3rd day showed mild inflammatory cell proliferation and absence of collagen.

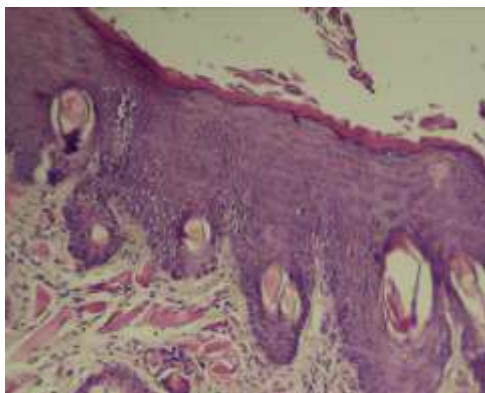


Figure (5): The study group at 7th days showed new well-defined keratinized squamous epithelium with well-defined rete ridge H&E stained slide (x10).

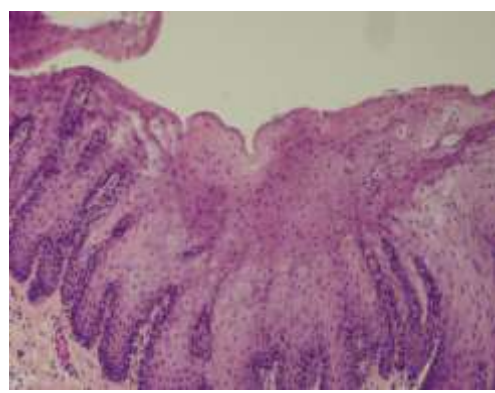


Figure (6): The control group at 7th days showed newly formed thin epithelium in the ulcer area H&E stained slide (x10).

Ulcer size results

Both the control and research groups displayed a reduction in ulcer size (mm²) beginning from the 3rd day and the lowest mean value (mm²) for final ulcer size was seen at them the 7th day. (Control and study

groups showed highly significant differences at all healing periods by using T-test, the mean of ulcer size was highly significantly higher (p<0.001) in control group than in study groups (Table 1).

Table (1): ANOVA test for the defiance in the size of the ulcers.

Day	Subgroups	Mean ±S.D	T-test	P- value
3 day	Study group	97.13 ± 1.45	37.52	0.00** HS
	Control group	150.73± 3.02	35.57	0.00** HS
7 day	Study group	31.47 ± 2.19	49.03	0.00** HS
	Control group	128.68 ± 1.25	83.27	0.00** HS

Inflammatory score results

The results of the study showed a lower mean inflammatory score in the study groups than the mean inflammatory score of the control group. Using the Mann-Whitney U test, the inflammatory score showed a high significant difference between the control and study

groups at all periods, which means the inflammatory score was lower in the study groups than in the control group during all durations (Table 2). The ANOVA test showed a substantial difference between the research and control groups, as found in Table 3.

Table (2): Descriptive statistics of the inflammatory score with the comparison between all groups and healing periods.

Day	Subgroups	N0	Min	Max	Mean
3 day	Study group	5	6	3	5
	Control group	5	4	4	4
7 day	Study group	5	1	2	1.33
	Control group	5	3	4	3.66

Table (3): Inflammatory scores between control and study groups in all durations by ANOVA test.

Day	Subgroups	Mean ±S.D	T-test	P- value
3 day	Study group	17.7± 3.02	14.13	0.00** HS
	Control group	9.13 ± 1.45	1.84	0.00** HS
7 day	Study group	31.47 ± 2.19	23.3	0.00** HS
	Control group	19.68 ± 1.25	5.2	0.00** HS

Blood vessel results

Over time, the research and control groups' mean blood vessel counts grew, with increase in the mean values in the

study groups than in the control group table 4.

Table (4): Descriptive statistic of blood vessel count with comparison between all groups and healing periods.

Day	Subgroups	N0	Min	Max	Mean
3 day	Study group	5	2	3	3
	Control group	5	4	6	5
7 day	Study group	5	7	9	8
	Control group	5	4	7	6

The results showed highly significant differences (p<0.001) in number of blood vessel

between durations for control and study groups using ANOVA test showed high significant difference between the group at 3 and 7 days table5.

Table (5): blood vessel count difference between control and study groups in all durations by ANOVA test.

Day	Subgroups	Mean ±S.D	T-test	P- value
3 day	Study group	17.7± 3.02	14.13	0.00** HS
	Control group	9.13 ± 1.45	1.84	0.00** HS
7 day	Study group	31.47 ± 2.19	23.3	0.00** HS
	Control group	19.68 ± 1.25	5.2	0.00** HS

Discussion

The adult New Zealand white rabbit was selected for this investigation because it fulfills a number of the desired requirements. This is partly because of its size and simplicity of handling. The rabbits are also useful because, at six months of age, they acquire

skeletal maturity and serve as a useful model for humans (44-45). Rabbits were used as the animal models in the current study's experimental protocols. The majority of clinical studies pertaining to the healing of wounds on the oral mucosa have favored

using rabbits as experimental models due to their well-known morphology and physiology of the oral cavity, as well as the similarities between their oral mucosa and that of humans, which is composed of subjacent connective tissue and surface epithelial tissues (45).

The results of present study demonstrated reduced ulcer size with treatment of amino acids mixture at all period of study (3rd, and 7th days) post wound than control group, which revealed highly significant differences in ulcer size between study groups and control group at 3rd, and 7th days. This result agree with (46) who found a significant reduction of excisional wound size treated with avocado oil, by topical application of the semisolid formulation of avocado oil (SSFAO 50%) or in natural avocado oil on the skin wound of rat, influenced the time for excisional wound closure. On the fifth day of treatment, an observed significant increase wound contraction in groups treated with SSFAO and in natural avocado oil when compared to the control. The results of this study demonstrated the role of amino acids as anti-inflammatory agent to decrease the inflammatory process at three period 3rd, and 7th days of study groups in comparing these periods with control group, the results showed significant differences in inflammatory score between study and control groups at all healing periods. The results of this study agree with (46). who reported topical application of the SSFAO 50% or in natural avocado oil on the skin wound of rat decreased the inflammatory process (reduce number of inflammatory cells) at the 3rd and 7th days of treatment. And agree with (47) Which used avocado oil in the healing the traumatic ulcer and showed modulate inflammatory response through high

availability of oleic acid present in the SSFAO, and competes with linoleic and linolenic acids that inhibited cyclooxygenases and lipooxygenases pathway. The results of this study showed adding of curcumin to avocado oil increase newly blood vessels formation through granulation tissue, there were significant difference between mean of new blood vessels of this group in compare with the mean in control group, especially at the 7th days post wound. This results agree with (48). that reported adding of polyphenol compound from curcumin to saturated fatty acid and polyunsaturated fatty acid (PUFA), administrated to enhance gingival wound healing in dog, showed potent angiogenesis effect that promote granulation tissue formation rich with new blood vessel that provided nourishment and eliminated the waste products from wound bed, in which additive effect induce endothelial cells activation, migration and proliferation with adequate secretion of angiogenesis growth factors.

Conclusion

Mixed amino acid was more effective in treatment of oral ulceration .systemic consumption of different amino acid was showed a reduction in ulcer size and increase percentage of ulcer healing with limited periods through increase wound contraction by activation of myofibroblast and reepithelialization by approximation of ulcer edge. Also the amino acids that used in treatment of oral ulcer cause enhancing reepithelializations, increase angiogenesis and reduce inflammatory reaction in the ulcer site. Which reduce both acute and chronic inflammatory cells infiltration in ulcer during early periods, activating mucosal keratinocyte

migration, proliferation to restore epithelial defect, enhancing endothelial cells to promote new blood vessels.

Recommendations

The worldwide utilization of amino acid since the use of medicine has greatly expanded. In order to ascertain the different characteristics, potencies, and configurations of these amino acids, as well as their adverse effects and toxicity, additional research is required. Other elements that must be taken into account include the type, size, and position of the wound as well as the vascular supply, infection, and other issues that could prevent the healing process.. This study indicated that systemic intake of amino acids with a controlled and low concentration could expedite healing as a supplement to or replacement for existing therapies.

Source of Funding: This research did not qualify for any kind of financial support of any kind

Ethical Clearance: This study was approved by the Ethics Committee of the College of Medicine, University of Diyala, and according to the ethical approval. (Document no. 2024MAH827).

Conflict of Interest: Non

References

1.Ten Cate, Arnold Richard, and Antonio Nanci. "Ten Cate's oral histology: development, structure, and function." (2013).

Doi :<https://lccn.loc.gov/2017028518>.

2.Casiglia, Jeffrey M., G. W. Mirowski, and F. FLOWERS. "Oral manifestations of systemic diseases." *Medscape reference* 35 (2013): 1-20.

3.Squier, Christopher A., and Mary J. Kremer. "Biology of oral mucosa and

esophagus." *JNCI Monographs* 2001.29 (2001): 7-15.

DOI:[10.1093/oxfordjournals.jncimonographs.a003443](https://doi.org/10.1093/oxfordjournals.jncimonographs.a003443)

4. Mak, Karen, et al. "Scarless healing of oral mucosa is characterized by faster resolution of inflammation and control of myofibroblast action compared to skin wounds in the red Duroc pig model." *Journal of dermatological science* 56.3 (2009): 168-180.

DOI:<https://doi.org/10.1016/j.jdermsci.2009.09.005>

5.Sjöqvist, Sebastian, et al. "Exosomes derived from clinical-grade oral mucosal epithelial cell sheets promote wound healing." *Journal of Extracellular Vesicles* 8.1 (2019): 1565264.

<https://doi.org/10.1080/20013078.2019.1565264>

6.Wang, Sha-Sha, et al. "The maintenance of an oral epithelial barrier." *Life sciences* 227 (2019): 129-136.

<https://doi.org/10.1016/j.lfs.2019.04.029>

7.National Institutes of Health. "NCI Dictionary of Cancer Terms-National Cancer Institute." *Website: https://www.cancer.gov/publications/dictionaries/cancer-terms*. Accessed March 18 (2019).

8.Brizuella, Melina, and Ryan Winters. "Histology, oral mucosa." (2021).

9.Squier, Christopher A., and Mary J. Kremer. "Biology of oral mucosa and esophagus." *JNCI Monographs* 2001.29 (2001): 7-15.

<https://doi.org/10.1093/oxfordjournals.jncimonographs.a003443>

10.Wang, Sha-Sha, et al. "The maintenance of an oral epithelial barrier." *Life sciences* 227 (2019): 129-

136.
<https://doi.org/10.1016/j.lfs.2019.04.029>
 11.Squier, Christopher A., and Mary J. Kremer. "Biology of oral mucosa and esophagus." *JNCI Monographs* 2001.29 (2001): 7-15.
<https://doi.org/10.1093/oxfordjournals.jncimonographs.a003443>
 12.Thomas, Aaron J., and Carol A. Erickson. "The making of a melanocyte: the specification of melanoblasts from the neural crest." *Pigment cell & melanoma research* 21.6 (2008): 598-610.
<https://doi.org/10.1111/j.1755-148X.2008.00506>
 13.Barrett, A. W., and C. Scully. "Human oral mucosal melanocytes: a review." *Journal of oral pathology & medicine* 23.3 (1994): 97-103.
<https://doi.org/10.1111/j.1600-0714.1994.tb01095.x>
 14.Feller, Liviu, et al. "Melanin: the biophysiology of oral melanocytes and physiological oral pigmentation." *Head & face medicine* 10.1 (2014): 1-7.
[doi: 10.1186/1746-160X-10-8](https://doi.org/10.1186/1746-160X-10-8)
 15.Yamaguchi, Yuji, Michaela Brenner, and Vincent J. Hearing. "The regulation of skin pigmentation." *Journal of biological chemistry* 282.38 (2007): 27557-27561.
 DOI:<https://doi.org/10.1074/jbc.R700026200>
 16.Wang, Yi-Ping, et al. "Langerhans cell counts in oral epithelial dysplasia and their correlation to clinicopathological parameters." *Journal of the Formosan Medical Association* 116.6 (2017): 457-463.
<https://doi.org/10.1016/j.jfma.2017.02.006>
 17.García Caballero, Lucía, et al. "Merkel cells of human oral mucosa express the pluripotent stem cell transcription factor Sox2." (2020).
<https://doi.org/10.14670/HH-18-231>
 18.Kingsmill, V. J., B. K. B. Berkovitz, and A. W. Barrett. "An immunohistochemical analysis of human Merkel cell density in gingival epithelium from dentate and edentulous subjects." *Archives of oral biology* 50.10 (2005): 883-887.
<https://doi.org/10.1016/j.archoralbio.2005.02.004>
 19.Kydd, William L., and Colin H. Daly. "The biologic and mechanical effects of stress on oral mucosa." *The Journal of prosthetic dentistry* 47.3 (1982): 317-329.
[https://doi.org/10.1016/0022-3913\(82\)90162-7](https://doi.org/10.1016/0022-3913(82)90162-7)
 20.Chen, Junning, et al. "Biomechanics of oral mucosa." *Journal of the Royal Society Interface* 12.109 (2015): 20150325.
<https://doi.org/10.1098/rsif.2015.0325>
 21.Fleisch, L., and J. C. Austin. "A histologic study of the response of masticatory and lining mucosa to mechanical loading in the vervet monkey." *The Journal of prosthetic dentistry* 39.2 (1978): 211-216.
[https://doi.org/10.1016/S0022-3913\(78\)80024-9](https://doi.org/10.1016/S0022-3913(78)80024-9)
 22.Tungare, Sujata, and Arati G. Paranjpe. "Drug induced gingival overgrowth." *StatPearls [Internet]*. StatPearls Publishing, 2022.
[https://doi.org/10.1016/S0022-3913\(78\)80024-9](https://doi.org/10.1016/S0022-3913(78)80024-9)
 23. Wertz, Philip W. "Lipids and the Permeability and Antimicrobial Barriers of the Skin." *Journal of lipids* 2018 (2018).
<https://doi.org/10.1155/2018/5954034>

24. Bearely, Shethal, and Steven W. Cheung. "Sensory topography of oral structures." *JAMA Otolaryngology-Head & Neck Surgery* 143.1 (2017): 73-80. doi:10.1001/jamaoto.2016.2772
25. Feldman, Ada T., and Delia Wolfe. "Tissue processing and hematoxylin and eosin staining." *Histopathology: methods and protocols* (2014): 31-43. DOI:10.1007/978-1-4939-1050-2_3
26. Gonsalves, Wanda C., Angela C. Chi, and Brad W. Neville. "Common oral lesions: Part I. Superficial mucosal lesions." *American family physician* 75.4 (2007): 501-506.
27. Nelson DL, Cox MM (2005). *Principles of Biochemistry (4th ed.)*. New York: W. H. Freeman. ISBN 0-7167-4339-6.
28. Rother, Michael, and Joseph A. Krzycki. "Selenocysteine, pyrrolysine, and the unique energy metabolism of methanogenic archaea." *Archaea* 2010 (2010). <https://doi.org/10.1155/2010/453642>
29. Binder HJ, Mansbach CM. Nutrient digestion and absorption. In: Boron WF, Boulpaep EL, eds. *Medical Physiology*. 3rd ed. Philadelphia, PA: Elsevier; 2017:chap 45.
30. Wu M, Xiao H, Ren W, et al. Therapeutic effects of glutamic acid in piglets challenged with deoxynivalenol. *Plos one*. 2014 ;9(7):e100591. DOI: 10.1371/journal.pone.0100591. PMID: 24984001; PMCID: PMC4077692. <https://doi.org/10.1371/journal.pone.0100591>
31. Smith QR. Transport of glutamate and other amino acids at the blood-brain barrier. *J Nutr*. 2000 Apr;130(4S Suppl):1016S-22S. doi: 10.1093/jn/130.4.1016S. PMID: 10736373. <https://doi.org/10.1093/jn/130.4.1016S>
32. Bergmeyer, Hans U., et al. "L-aspartate and L-asparagine." *Methods of enzymatic analysis*. Academic Press, 1974. 1696-1700. <https://doi.org/10.1016/B978-0-12-091304-6.50015-X>
33. Holeček, Milan. "Aspartic acid in health and disease." *Nutrients* 15.18 (2023): 4023. <https://doi.org/10.3390/nu15184023>
34. White, Phillip J., and Christopher B. Newgard. "Branched-chain amino acids in disease." *Science* 363.6427 (2019): 582-583. DOI: 10.1126/science.aav0558
35. Howatson, Glyn, et al. "Exercise-induced muscle damage is reduced in resistance-trained males by branched chain amino acids: a randomized, double-blind, placebo controlled study." *Journal of the international Society of Sports Nutrition* 9.1 (2012): 20.
36. Ra, Song-Gyu, et al. "Combined effect of branched-chain amino acids and taurine supplementation on delayed onset muscle soreness and muscle damage in high-intensity eccentric exercise." *Journal of the International Society of Sports Nutrition* 10.1 (2013): 51. <https://doi.org/10.1186/1550-2783-10-51>
37. Che, L., et al. "Effects of dietary arginine supplementation on reproductive performance and immunity of sows." *Czech J. Anim. Sci* 58.4 (2013): 167-175. DOI:10.17221/6711-CJAS
38. Kalil, Andre C., and Robert L. Danner. "L-Arginine supplementation in sepsis: beneficial or harmful?." *Current opinion in critical care* 12.4 (2006): 303-308.

DOI:10.1097/01.ccx.0000235206.92697.bf

39.Kesici, Ugur, et al. "Effects of glutamine on wound healing." *International wound journal* 12.3 (2015): 280-284. doi: [10.1111/iwj.12098](https://doi.org/10.1111/iwj.12098).

40.Hassan, Manar Abd Alrazaq, and Nada MH AL-Ghaban. "Histological Evaluation of the Effect of Local Application of Grape Seed Oil on Healing Process of Extracted Tooth Socket in Rabbits." *Diyala Journal of Medicine* 17.2 (2019): 70-84. DOI:10.26505/DJM.17024670515

41. Hassan, Manar Abd Alrazaq, and Nada MH AL-Ghaban. "Immunohistochemical Localization Of Bone Morphogenic Protein-2 In Extracted Tooth Socket Treated By Local Application Of Grape Seeds Oil In Rabbits." *Biochemical & Cellular Archives*(2020). 20.1. DOI:10.35124/bca.2020.20.1.581

42. Hassan, Manar Abd Alrazaq, Ansam Mahdi Khalel, and Asmaa A. Ajwad. "Histological and Histomorphometric illustration the endochondral ossification of the mandibular angle defect repair in rats after oral stimulation with bisphosphonate treatment (an in vivo study)." *Diyala Journal of Medicine*; (2024):111-124, Volume 26, Issue 2 <https://doi.org/10.26505/djm.v26i2.1102>

43.Tawfieq, Ali Hakiem, et al. "Localization of the position of vital anatomical structures in the lateral wall of maxillary sinus during different surgical intervention using cone beam computed tomography." *Diyala Journal of*

Medicine; December 2023 Volume 25, Issue 2.

<https://doi.org/10.26505/djm.v25i2.105144>. Sa, Guoliang, et al. "Histological features of oral epithelium in seven animal species: As a reference for selecting animal models." *European Journal of Pharmaceutical Sciences* 81 (2016): 10-17. <https://doi.org/10.1016/j.ejps.2015.09.019>.

45.Hassan, Manar Abd Alrazaq. "Histological Determination of Cinnamon and Olive Oil Extract on Traumatic Oral Ulcer in Laboratory Rabbit." *Diyala Journal of Medicine* 27.1 (2024): 111-122. DOI: [10.26505/DJM.27018230327](https://doi.org/10.26505/DJM.27018230327).

46.de Oliveira, Ana Paula, et al. "Effect of semisolid formulation of Persea americana Mill (avocado) oil on wound healing in rats." *Evidence-Based Complementary and Alternative Medicine* 2013. 472382,:1–8. <https://doi.org/10.1155/2013/472382>

47.Shamsah M. Sahib. An Evaluation of the Effect of Curcumin and Natural Avocado Oil on Induced Traumatic Oral Ulceration in Rabbits; (Clinical, Histological and Immunohistochemical Study).thesis submitted to the college of dentistry, baghdad university;2020, 138.

48.Habiboallah, Ghanbari, et al. "Histological evaluation of Curcuma longa–ghee formulation and hyaluronic acid on gingival healing in dog." *Journal of ethnopharmacology* 120.3 (2008): 335-341. <https://doi.org/10.1016/j.jep.2008.09.011>

التقييم النسيجي والنسجي لشفاء جروح تجويف الفم لدى الأرانب عن طريق تغذية الأحماض الأمينية القابلة للامتصاص

منار عبد الرزاق حسن^١

الملخص

خلفية الدراسة: قرحة الفم المؤلمة هي آفة منخفضة ومحدودة بشكل جيد مع خلل ظهاري مغطى بجلطة الفيبرين، مما يؤدي إلى مظهر أصفر-أبيض، يحدث بسبب إصابة كيميائية أو ميكانيكية أو حرارية للغشاء المخاطي للفم مع تآكل مؤلم. الأحماض الأمينية ضرورية لشفاء الجروح لأنها تعزز نمو النسيج الضام وكذلك تنشيط وتكاثر الخلايا الليفية.

اهداف الدراسة: تقييم تأثير التطبيق المنهجي لجمع الأحماض الأمينية (تناول الفم) في علاج تقرح الفم المؤلم خلال فترة زمنية محددة عن طريق التقييم النسيجي والنسجي لشفاء الأنسجة الرخوة.

المرضى والطرائق: تم استخدام ٢٠ ذكر أرنب بالغ بوزن حوالي ٧٠٠-٩٠٠ كغم وأعمار حوالي (٦-٨) أشهر حيث تم استخدامها في هذه الدراسة التجريبية. تم إنشاء القرحة المؤلمة بقطر (٨ مم)، و(١ مم) بواسطة مثقاب ماسي دائري جراحي في الغشاء المخاطي للخد الأيمن، ثم تم تقسيم المجموعات إلى مجموعتين، ١٠ أرانب للمجموعة الضابطة التي تركت تلتئم بشكل طبيعي، و ١٠ أرانب للمجموعة التجريبية التي يستخدم يومياً خليط من الأحماض الأمينية نظامياً من خلال خلطه مع الماء لمدة شهر. تمت التضحية بالحيوانات خلال فترات شفاء مدتها ٣ و ٧ أيام وتم فحص الأنواع تشريحياً بعد التحضير النسيجي للقرحة المؤلمة.

النتائج: أظهرت النتائج النسيجية والنسجية انخفاض الالتهاب، وتسريع إعادة تنسج سطح القرحة، وتولد الأوعية الدموية بشكل أفضل، وتعزيز إعادة تشكيل المصفوفة خارج الخلية مما يؤدي إلى تعزيز نضج الأنسجة والشفاء الكامل في جميع الحالات. مجموعات الدراسة منها في المجموعة الضابطة.

الاستنتاجات: الدواء الكيميائي الذي يمثله التطبيق الجهازى للأحماض الأمينية فعال في تسريع شفاء القرحة المصابة في المجموعة التجريبية مقارنة بالمجموعة الضابطة عن طريق تكاثر الخلايا المتسارع وإعادة تنسج الغشاء المخاطي.

الكلمات المفتاحية: القرحة المؤلمة، الأحماض الأمينية، إعادة النظائر.

البريد الإلكتروني: manar@uodiyala.edu.iq

تاريخ استلام البحث: ٢٧ آذار ٢٠٢٤

تاريخ قبول البحث: ١٣ حزيران ٢٠٢٤

^١ جامعة ديالى/ كلية طب الاسنان/ ديالى/ العراق.