


Evaluation of oral health status for a group of orthodontic patients

Karrar Nihad Muhamed Al-Mujamii (PhD)¹, Hajer Ali Ahmed Hentati  (PhD)², Zainab Hafidh Taha (BDS,HD)³, Abdulhameed Salim Altaee (MSc)⁴

¹ Department of Pathology and Forensic Dentistry, College of Medicine, University of Diyala, Diyala, Iraq.

² Faculty of Dental Medicine of Monastir, University of Monastir, Tunisia.

³ Department of Preventive Dentistry, Specialized dental health center, Diyala Health Directorate, Diyala, Iraq.

⁴ Department of Oral and Maxillofacial surgery, Specialized dental health center, Diyala Health Directorate, Diyala, Iraq.

Abstract

OPEN ACCESS

Correspondence Address: Karrar Nihad Muhamed Al-Mujamii
Department of Pathology and Forensic Dentistry, College of Medicine, University of Diyala, Diyala, Iraq.

Email: dr.karrar82@gmail.com

Copyright: ©Authors, 2023, College of Medicine, University of Diyala. This is an open access article under the [CC BY 4.0](http://creativecommons.org/licenses/by/4.0/) license

(<http://creativecommons.org/licenses/by/4.0/>)

Website:

<https://djm.uodiyala.edu.iq/index.php/djm>

Received: 24 October 2023

Accepted: 21 December 2023

Published: 25 December 2023

Background: Malocclusion and fixed orthodontic appliance convoluted the ordinary oral hygiene measures, which may lead to accumulation and prolonged retention of dental plaque on tooth surfaces particularly around the orthodontic brackets and auxiliaries of the fixed orthodontic appliance.

Objective: To evaluate the oral health status among a group of orthodontic patients by evaluating the plaque, gingival, calculus, and Enamel Decalcification indices.

Patients and Methods: This study was conducted among 128 persons (64 with fixed orthodontic appliance as a study group and 64 without fixed orthodontic appliance as a control group. An assessment of related clinical parameters as plaque, gingival, as well as enamel decalcification indices were done.

Results: The present study revealed that the mean plaque, gingival, as well as enamel decalcification indices for the total sample were (1.182±0.356), (1.230±0.269), and (1.329±0.413) respectively. Additionally, all of these indices were higher among study group (fixed orthodontic patient) than among control group (persons without orthodontic appliance) with statistically significant difference among groups for each.

Conclusion: Fixed orthodontic appliance is an effective plaque retentive factor that accumulate dental plaque which is the main causative factor for development of enamel white spot lesion and periodontal disease.

Keywords: Oral health status, Fixed orthodontic appliance, white spot lesion, periodontal disease.

Introduction

One of well-known oral disorders is malocclusion, this disorder has the ability to increase the risk of other oral diseases as dental caries and periodontal disease. Thus, it is very important to maintain a healthy periodontium during the period of orthodontic treatment because the fixed

orthodontic appliance may accumulate the dental plaque which in turn contribute to develop dental caries as well as periodontal disease [1,2,3,4].

The dental plaque pathogenicity may be enhanced by fact that, in dental plaque biofilm the bacteria may have increased

antibiotic and chemotherapeutic agent resistance and less phagocytized by the host inflammatory cell, for this reason the dental plaque biofilm control is the major dental professional objective for maintaining an optimal oral health. In addition to providing a source of acid production, the dental plaque provides a physical barrier which limit the acid diffusion away from the tooth enamel surface and thus preventing enamel remineralization by calcium and phosphate ions from saliva [5].

In fixed orthodontic appliances patients it is difficult to achieve good oral hygiene because these appliances make obstruction for the typical mechanical brushing, also after meal the food may trapped around bonded orthodontic brackets and under the arch wires, so a good oral health maintenance may become challenged and thus increasing the risk of enamel demineralization, periodontal disease, as well as teeth staining. The numerous components of fixed orthodontic appliance may encourage the accumulation and proliferation of dental plaque and periodontal microorganisms (*Treponema denticola* and *Porphyromonas gingivalis*) respectively thus generating an excessive or unfavorable forces on teeth and

their supporting structures resulting in an elevated risk of periodontal diseases [6].

Patients and Methods

The present study was conducted between June 2023 and September 2023 at orthodontic department in second specialized dental health center in Baquba City/ Diyala Governorate/ Iraq for orthodontic patients aged between 30 and 35 years old after expressing the research to those patients and obtaining an informed consent from them. For Standardization purposes all the persons included in this study were male and brush their teeth twice a day. The total sample size was 128 person those include 64 persons in study group (with fixed orthodontic appliance) and the remaining (without orthodontic appliance) in control group.

Concerning the plaque index, it was assessed according to previously described criteria by Silness and Loe where the dental plaque biofilm thickness at the gingival area of the entire dentition was assessed ⁽⁷⁾. Thus, by the naked eye and under good lighting, mouth mirror as well as periodontal probe were used in scoring the dental plaque biofilm immediately adjacent to gingiva margin, Figure (1) and (2).

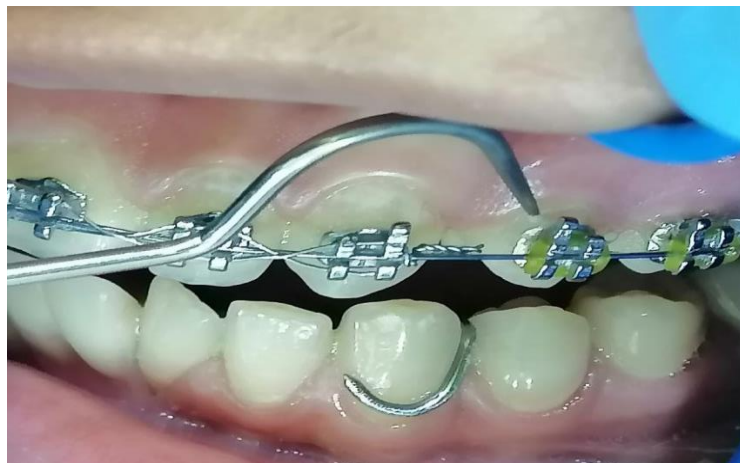

Figure (1): Dental plaque biofilm scoring immediately adjacent to gingiva margin

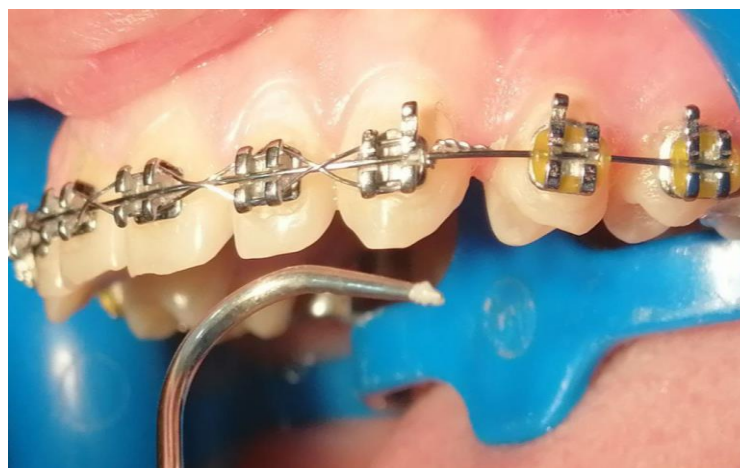

Figure (2): Dental plaque biofilm sample

All teeth surfaces including distal, facial, mesial and lingual\ palatal of the entire dentition was typically examined by starting from the upper right second molar and continued over the midline of the jaw to the upper left second molar. Regarding the teeth which are located on the right side of the jaw midline, the sequence of examination might include distal, facial and mesial, and the opposite was true for the teeth which are located on the left side of midline where the sequence of examination might include mesial, facial, and distal. Concerning the palatal surface of the entire dentition, they

were assessed starting from the upper left second molar through the midline of the jaw to the upper right second molar. Moreover, in the lower jaw the entire dentition was examined starting from the lower left second molar and preceding through the midline to the lower right second molar. Concerning the sequence of surfaces examination, it was opposite to that of upper jaw where the sequence was distal, facial, and mesial for the teeth that are located on the left side, and mesial, facial, and distal for the teeth that are located on the right side of the jaw midline. Additionally, the lingual surfaces of lower

dentition were scored starting from the lower left second molar and preceding through the midline to the lower right second molar [8]. The plaque index examination preceded the calculus and gingival indices examination.

Concerning the gingival condition, it was evaluated according to the criteria that were presented by Loe and Silness. The sequence of the examination was done similarly to that used for dental plaque biofilm assessment, additionally in this study the periodontal probe was used for examining the entire dentition. Furthermore, the gingivitis severity was assessed according to the classification presented by Loe and Silness⁽⁹⁾. The presence or absence and distribution of white spot lesions around the bonded

orthodontic brackets might be assessed on the basis of Enamel Decalcification Index criteria described by Banks and Richmond [10]. In accordance to this index, the right second premolar to left second premolar in both dental arches were examined, in this study the molars were excluded due to the presence of cemented orthodontic bands which make the visibility of white spot lesions difficult. The facial surfaces of included teeth were examined after removing dental plaque and dryness. After that dividing the facial surface of each included teeth into four areas that include the gingival, mesial, distal, as well as incisal\occlusal around the orthodontic bracket, Figure (3).

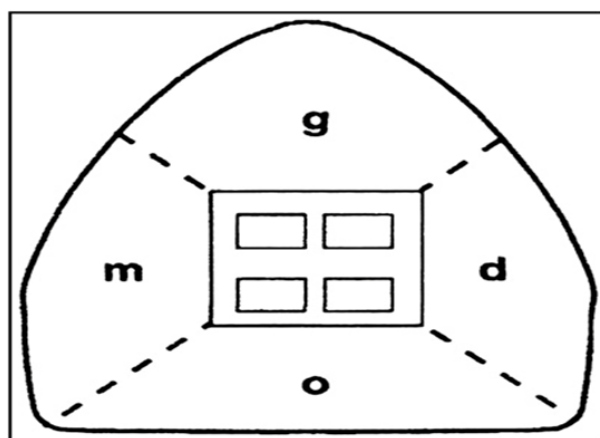


Figure (3): Enamel Decalcification Index (Banks and Richmond, 1994)

Statistical Analysis

Data description, analysis and presentation were performed using Statistical Package for social Science (SPSS version -22, Chicago, Illionis, USA), Independent Sample t test used to test the difference between the two groups. Level of significance as: Not significant $P > 0.05$, Significant $P < 0.05$. Additionally.

Results

Table (1) shows that the mean plaque index for the total sample was (1.182 ± 0.356) , additionally it was higher among study group (1.531 ± 0.621) than among control group (0.833 ± 0.277) with statistically significant difference.

Table (1): Plaque Index (Mean±SD) among groups

Group	PII	Statistical test		
	Mean ± SD	Independent sample -t-test	df	p-value
Study	1.531±0.621	45.868	126	0.000
Control	0.833±0.277			
Total	1.182±0.356			

* Not significant at p>0.05, Significant at p<0.05, df= degree of freedom

Table (2) shows that the mean gingival index for the total sample was (1.230±0.269), additionally the study group shows a moderate type of gingivitis while the control group shows a mild type where the mean

gingival index was higher among study group (1.480±0.128) than among control group (0.980±0.324) with statistically significant difference .

Table (2): Gingival Index (Mean±SD) among groups

Group)	GI	Statistical test		
	Mean ± SD	Independent sample -t-test	df	p-value
Study	1.480±0.128	16.846	38	0.000
Control	0.980±0.324			
Total	1.230±0.269			

* Not significant at p>0.05, Significant at p<0.05, df= degree of freedom

Table (3) shows that the mean enamel decalcification index for the total sample was (1.329±0.413), additionally it was higher

among study group (1.718±0.170) than among control group (0.940±0.553) with statistically significant difference .

Table (3): Enamel Decalcification Index (Mean±SD) among groups

Group)	EDI	Statistical test		
	Mean ± SD	Independent sample -t-test	df	p-value
Study	1.718±0.170	19.405	38	0.000
Control	0.940±0.553			
Total	1.329±0.413			

* Not significant at p>0.05, Significant at p<0.05, df= degree of freedom

Discussion

Most of patients with malocclusion including those who are treated with fixed orthodontic appliance have a relatively large number of retention sites due to their teeth irregularity . In present study the mean plaque index was significantly higher among study group than control group this due to the presence of fixed orthodontic appliance that considered as an effective plaque retentive

factor . Additionally, the oral ecology appeared to be altered by insertion of fixed orthodontic appliance as the orthodontic treatment considered as a serious invasion of the oral environment because it provides a solid surface retentive sites of appliance which in turn favor the colonization of microorganisms that introduce another variable into the system [11,12,13]. This finding is in agreement with other studies

which showed that the orthodontic patients had higher amount of dental plaque as compared to non-orthodontic patients [14, 15].

Concerning gingival condition, the present study reveals that the study group have moderate gingivitis while control group have mild gingivitis where the gingival index was significantly higher among study than control group due to dental plaque accumulation around the components of fixed orthodontic appliance, this accumulated dental plaque is considered as an important causative factor for development of gingivitis, this finding is in agreement with other previous study [16, 17, 18].

Regarding the white spot lesion development, the present study shows that mean enamel decalcification index was significantly higher among study group than control group, this may be due to the accumulation of dental plaque around the orthodontic brackets which make the removal of this dental plaque difficult, so this accumulated dental plaque may provide a reservoir for cariogenic bacteria which invade between the enamel surface and adhesive material as a result of polymerization shrinkage of the adhesive material, then these bacteria metabolize the carbohydrate and produce acid which in turn demineralize the tooth enamel especially around the orthodontic brackets, this finding is in agreement of other previous study [19, 20, 21].

Conclusions

Patients with fixed orthodontic appliance are at high risk for developing white spot lesion and periodontal disease as those patients may

show a high rate of gingivitis and dental plaque accumulation around the components of fixed orthodontic appliance which make the removal of dental plaque difficult. As the dental plaque considered as causative factor for development of dental caries and periodontal disease, so it is important to maintain a healthy periodontium during the period of orthodontic treatment.

Recommendations

Further studies needed to be conducted with larger sample size.

Source of funding: The current study was funded by our charges with no any other funding sources elsewhere.

Ethical clearance: Ethical approval was obtained from the College of Medicine / University of Diyala ethical committee for this study.

Conflict of interest: Nil

References

- [1] Paduano S., Rongo R., Bucci R, et al. Is there an association between various aspects of oral health in Southern Italy children? An epidemiological study assessing dental decays, periodontal status, malocclusions and temporomandibular joint function. *European Journal of Paediatric Dentistry*, 2018. 19(3): p 176-180
- [2] Sim HY, Kim HS, Jung DU, Lee H, Lee JW, Han K, et al. Association between orthodontic treatment and periodontal diseases: Results from a national survey. *Angle Orthod.*, 2017. 87: p 651–7
- [3] Ahovuo-Saloranta A, Forss H, Walsh T, Nordblad A, Mäkelä M, Worthington HV. Pit and fissure sealants for preventing dental decay in permanent teeth. *Cochrane Database Syst Rev.*, 2017. 7: p 001830.

- [4] Javali MA, Betsy J, Al Thobaiti R, Alshahrani R, and AlQahtani, HA. Relationship between Malocclusion and Periodontal Disease in Patients Seeking Orthodontic Treatment in Southwestern Saudi Arabia. *Saudi J Med Med Sci.*, 2020. 8(2): p 133–139.
- [5] Rudak O, & Andruškienė J. Importance of individual oral hygiene in oral health maintenance: scientific literature review. *Professional Studies: Theory & Practice*, 2019. 5(20): p 42-52.
- [6] Mei L, Chieng J, Wong C, Benic G, Farella M. Factors affecting dental biofilm in patients wearing fixed orthodontic appliances. *Progress in Orthodontics*, 2017. p 18: 4.
- [7] Silness J & Loe H. Periodontal disease in pregnancy. Correlation between oral hygiene and periodontal condition. *Acta Odont Scand*, 1964. 22: 121-35.
- [8] Wei S and Lang N. Periodontal epidemiological indices for children and adolescents: II. Evaluation of oral hygiene. *The American Academy of Pedodontics*, 1982. 4(1): p 65.
- [9] Loe H. & Silness J. Periodontal disease in pregnancy I. *Acta Odont Scand*, 1963. 21: 533-551.
- [10] Banks P.A & Richmond S. Enamel sealants: a clinical evaluation of their value during fixed appliance therapy, *European Journal of Orthodontics*, 1964. 16 (1): p 19–25
- [11] Cerroni S, Pasquantonio G, Condò R, Cerroni L. Orthodontic Fixed Appliance and Periodontal Status: An Updated Systematic Review. *Open Dent J.*, 2018. 12: p 614-622.
- [12] Edith LC, Montiel-Bastida NM, Leonor SP, Jorge, AT. Changes in oral environment during four stages of orthodontic treatment. *Korean J Orthod*, 2010. 40: pp.95-105.
- [13] Reichardt E, Geraci J, Sachse S, Rödel J, Pfister W, Löffler B, Wagner Y, Eigenthaler M, Wolf M. Qualitative and quantitative changes in the oral bacterial flora occur shortly after implementation of fixed orthodontic appliances. *American Journal of Orthodontics and Dentofacial Orthopedics*, 2019. 156(6): p 735–744.
- [14] Pithon MM, dos Santos RL, Nascimento LE, Osorio Ayre A, Alviano D, Bolognese AM. Do self-ligating brackets favor greater bacterial aggregation?. *Braz J Oral Sci*, 2011. 10: pp.208–212.
- [15] Bevinagidad S, Setty S, Patil A, & Thakur S. Estimation and correlation of salivary calcium, phosphorous, alkaline phosphatase, pH, white spot lesions, and oral hygiene status among orthodontic patients. *Journal of Indian Society of Periodontology*, 2020. 24(2): p 117–121.
- [16] Lucchese A, Bondemark L, Marcolina M, Manuelli M. Changes in oral microbiota due to orthodontic appliances: A systematic review. *J. Oral. Microbiol*, 2018. 10: p 1476645.
- [17] Sreenivasan P.K and Prasad K.V.V. Distribution of dental plaque and gingivitis within the dental arches. *J. Int. Med. Res.*, 2017. 45: p 1585–1596.
- [18] Al-Saidy A.H. The Periodontal Health Status Among Patients Attending the Periodontal Department, School of Dentistry , Faculty of Medical Science, Sulaimani University, Kurdistan Region ,Iraq. *Diyala Journal of Medicine*, 2013. 4 (1): p 1- 14.
- [19] Mirza K.B. The Prevalence And Severity of Periodontal Disease in Different

Stages of Pregnancy and in Women Taking Oral (Contraceptive Pills) in Sulaimani City, Kurdistan Region, Iraq. *Diyala Journal of Medicine*, 2013. 4 (1): p 61- 73.

[20] Khoroushi M and Kachuie M. Prevention and treatment of white spot lesions in orthodontic patients. *Contemp Clin Dent*, 2017. 8: p 11-9.

[21] Salman O and Al-Ani R. Evaluation of Microleakage under Sapphire Brackets Bonded with Three Different Orthodontic Adhesives after Thermocycling and Water Storage (An in-vitro Study). *Indian Journal of Forensic Medicine & Toxicolog*, 2021. 15 (3): p 1457-1462.

تقييم الحالة الصحية للفم لمجموعة من مرضى تقويم الأسنان

كرار نهاد محمد المجمالي¹, هاجر علي احمد حننيتي², زينب حافظ طه³, عبد الحميد سالم الطائي⁴

المخلص

خلفية الدراسة: سوء الإطباق وأجهزة تقويم الأسنان الثابتة تؤدي إلى تعقيد إجراءات نظافة الفم العادية، مما قد يؤدي إلى تراكم اللويحة السنية والاحتفاظ بها لفترة طويلة على أسطح الأسنان خاصة حول الأقواس التقويمية والمساعدة لجهاز تقويم الأسنان الثابت.

اهداف الدراسة: لتقييم الحالة الصحية للفم بين مجموعة من مرضى تقويم الأسنان من خلال تقييم مؤشرات اللويحة واللثة والجير ومؤشرات إزالة الكلس من المينا.

المرضى والطرائق: أجريت هذه الدراسة بين 128 شخصاً (64 شخصاً يستخدمون جهاز تقويم الأسنان الثابت كمجموعة دراسة و64 شخصاً لا يستخدمون جهاز تقويم الأسنان الثابت كمجموعة مراقبة. تم تقييم المؤشرات السريرية ذات الصلة مثل البلاك واللثة وكذلك مؤشرات إزالة الكلس بالمينا.

النتائج: كشفت الدراسة الحالية أن متوسط مؤشرات البلاك واللثة وكذلك إزالة الكلس في المينا للعينة الكلية كانت (0.269 ± 1.230) , (0.356 ± 1.182) و (0.413 ± 1.329) على التوالي. بالإضافة إلى ذلك، كانت جميع هذه المؤشرات أعلى بين مجموعة الدراسة (مرضى تقويم الأسنان الثابت) عنها بين مجموعة التحكم (الأشخاص الذين ليس لديهم جهاز تقويم الأسنان) مع وجود فروق ذات دلالة إحصائية بين المجموعات لكل منها.

الاستنتاجات: جهاز تقويم الأسنان الثابت هو عامل فعال في تكون و تراكم البلاك وهو العامل المسبب الرئيسي لتطور آفة البقع البيضاء في المينا وأمراض اللثة.

الكلمات المفتاحية: الحالة الصحية للفم، جهاز تقويم الأسنان الثابت، آفة البقعة البيضاء، أمراض اللثة

البريد الإلكتروني: dr.karrar82@gmail.com

تاريخ استلام البحث: 24 تشرين الأول 2023

تاريخ قبول البحث: 21 كانون الأول 2023

¹ كلية الطب – جامعة ديالى – ديالى - العراق

² كلية طب الاسنان – جامعة منبستر – تونس

^{3,4} مركز صحة الأسنان التخصصي - دائرة صحة ديالى – ديالى - العراق